

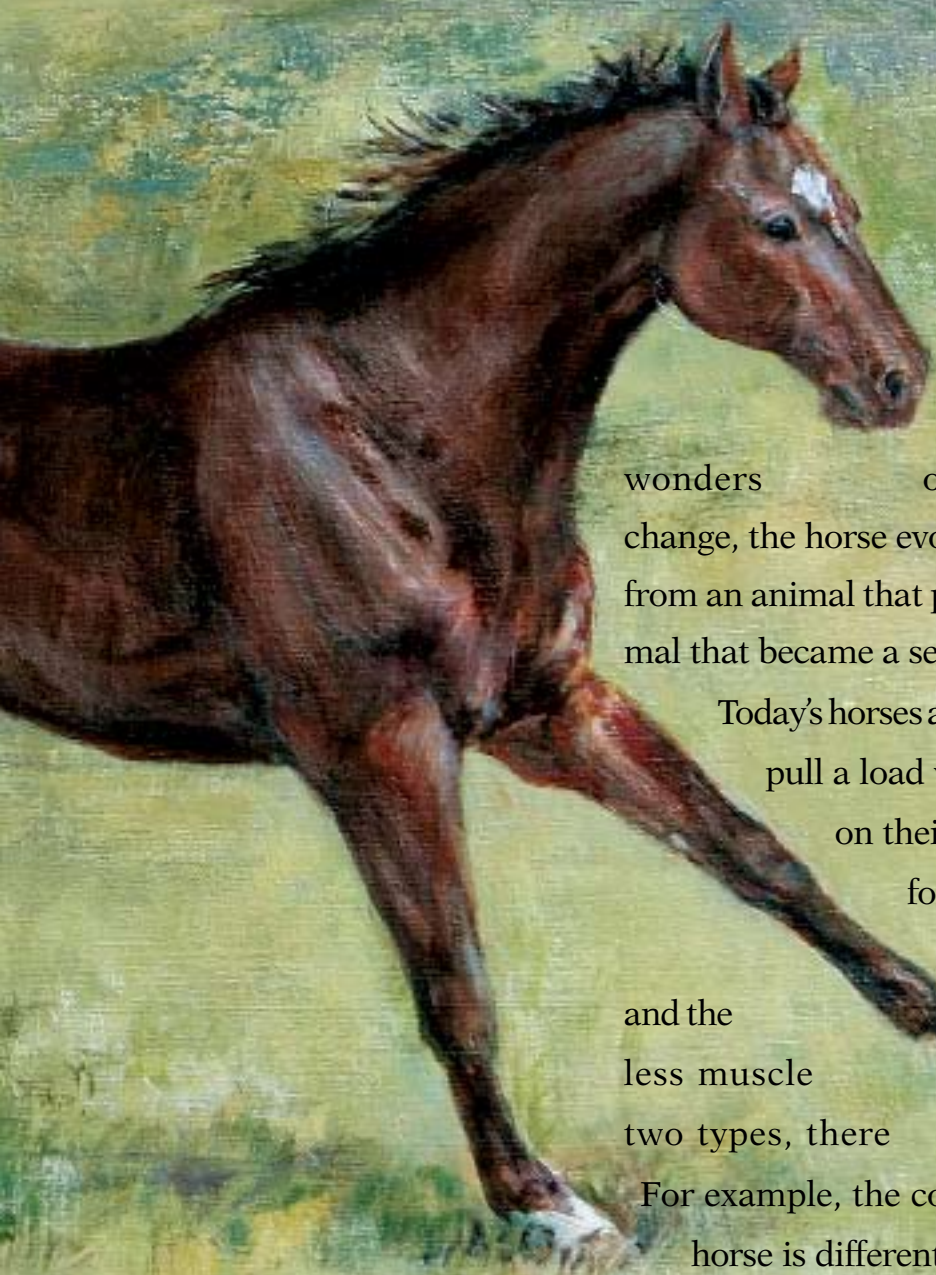
Anatomy &



This first article of a 12-part series on equine anatomy and physiology discusses basic terminology, the horse's largest organ, and how horses and humans are alike (and different)

Physiology

BY LES SELLNOW



The evolution of the horse from a tiny, four-toed animal, perhaps no more than one foot tall, to the variety of equines in existence today, is one of the wonders of nature. During that process of change, the horse evolved over many thousands of years from an animal that predators hunted for food to an animal that became a servant and friend for mankind.

Today's horses are designed to do one of two things—pull a load with their shoulders or carry riders on their backs. The type of horses utilized for these respective tasks varies a good deal; one is large and ponderous and the other is lighter-boned with less muscle mass. Even within these two types, there are significant differences. For example, the conformation of a roping or cutting horse is different from that of the American Saddlebred. Yet there is a basic sameness to anatomy.

DR. ROBIN PETERSON ILLUSTRATION

In this opening article of our 12-part series on equine anatomy and physiology, we will attempt to paint a picture of how today's horse is constructed and what this means in the realm of form to function. We will not be quoting a lot of sources, for the most part, because the information to be presented is an amalgamation of what has been recorded in thousands of scientific papers, textbooks, and manuals as knowledge has been gained and disseminated through the years. However, we would be remiss in not calling attention to two valuable sources upon which we shall draw heavily. Both are written at the layman level. They are *Horses and Horsemanship* by the late M.E. Ensminger, BS, MA, PhD, and *The Coloring Atlas of Horse Anatomy* by Robert A. Kainer, DVM, MS, and Thomas O. McCracken, MS, both of whom were at Colorado State University.

McCracken, who resigned from Colorado State in 1994 to enter private business, has authored seven books, and today he is president of Biographix, LLC. Early in his career, McCracken spent two years in Saudi Arabia as chief medical illustrator for the King Faisal Specialist Hospital and Research Center in Riyadh. Through the years, he has received many honors and awards of excellence for his work.

Kainer joined the anatomy faculty at Colorado State in 1961 and remained there for 27 years. He, too, has won a variety of awards and honors for his work.

Needless to say, since there are entire books written on equid anatomy and physiology, it would be impossible to address the entire animal in one article. Therefore, this month we look in-depth at the horse's largest organ, its skin, and details of the nomenclature used to discuss anatomy and physiology, as well as lightly touch on structures that will be covered in-depth in the coming year. In the months ahead we'll have articles on joints, the foreleg, the hind limb, the hoof, the head and neck, the back, muscles, tendons and ligaments, and the digestive, circulatory, respiratory, and reproductive systems.

A Glossary to Get You Started

We will begin this discussion of equine anatomy with Kainer's and McCracken's

explanation of terminology that is routine for veterinarians and researchers, but can be confusing to some horse owners. Along with the two authors' terminology, we'll add examples to demonstrate how the terminology might be employed. Understanding the terminology is essential when discussing various conditions with a veterinarian.

Here is some terminology, accompanied by illustrations, to help you visualize:

On Side—The horse's left side; also called near side. Example: Normally, the side on which we mount and dismount.

Off Side—Right side of the horse; also called far side. Example: One theory of why we mount from the left instead of the right is that warriors and soldiers of old generally carried a sword on the left side and this would get in the way if swinging up from the right or off side of the horse.

Dorsal—Parts of the horse's anatomy toward his back (dorsum). Example: The point of the croup is dorsal to the stifle.

Ventral—Anatomy toward the belly (venter). Example: The stallion's reproductive organs are ventral to his flank.

Cranial—That part of the horse's structure above the knees and hocks located closer to the skull (cranium). Example: The withers are cranial to the tail.

Caudal—That part of the horse's structure above the knees and hocks located closer to the tail (cauda). Example: The

horse's back is caudal to his neck.

Rostral—That part of the structure located closer to the nose (rostrum). Example: The eyes are rostral to the ears.

Proximal—A location toward the attached end of a limb. Example: The proximal end of the cannon bone connects with the knee.

Distal—Indicates a location toward the free end of a limb—the part that is farther away from the body. Example: The distal end of the cannon bone connects with the long pastern bone or third phalanx.

Median Plane—This divides the horse's body into right and left halves (median means in the middle).

Sagittal Plane—Any plane parallel to the median plane. Example: A plane dividing the right and left sides of a hoof.

Medial—Structures located closer to the median plane. Example: When you look at a horse's left side, you see the medial surfaces of his *right* limbs.

Lateral—Structures located away from the median plane. Example: When you look at a horse's left side, you see the lateral surfaces of his *left* limbs.

Transverse Plane—Passes through the head, trunk, or limb perpendicular to the part's long axis. Example: An ultrasound image gives a transverse view of the limb.

Dorsal Plane—Passes through a body part parallel to its dorsal surfaces.



DR. ROBIN PETERSON ILLUSTRATION

There are some similarities between human and equine anatomy, but there are a great many differences as well. For example, the human knee and the equine stifle have a lot in common. The equine radius is similar to the human forearm. The equine carpal or knee bones are similar to human wrist bones. And the equine splint bones compare to human fingers.

There are subtle shifts in terminology as we move about the equine anatomy. For example, the two writers point out, “Distal to and including the carpus (knee), dorsal replaces cranial and palmar replaces caudal. Distal to and including the hock, dorsal replaces cranial, but plantar replaces caudal.” This means that when you are talking about the lower limbs, you use the word dorsal to mean frontward instead of cranial, and instead of using caudal to mean rearward, you use palmar (for the front limb) or plantar (for the hind limb).

The solar surface of the hoof is the part that contacts the ground.

When looking at a horse’s limb from the front, an axial structure is located toward the axis (center of the limb) and an abaxial structure is located away from the axis.

Classifying the Horse

Before leaving our *Atlas* authors, we’ll pass along their explanation of proper terminology for this animal we are discussing, along with what they consider to be identifying characteristics:

“Horses and their close relatives, donkeys and zebras, are in the mammalian order of odd-toed, hoofed animals (*Perissodactyla*) as are their distant relatives, rhinoceroses and tapirs. The horse, *Equus caballus*, is an equid, a member of the horse family *Equidae*. The adjective equine is frequently used improperly as a noun.”

They point out that characteristics of equids include:

- 1) Highly specialized limbs, each with one digit (the third) and with the main muscle mass of the limb situated close to the body’s trunk.
- 2) Large paranasal sinuses within the skull.
- 3) Guttural pouches, which are large out-pocketings of the auditory tubes that extend from the nasopharynx to the middle ears.
- 4) High-crowned permanent teeth that grow for a long time—a feature used to determine the age of a horse.
- 5) A simple stomach followed by a long small intestine and a large, complicated large intestine where fermentation of feed occurs.

- 6) Well-developed skin glands.
- 7) Large heart and lungs.
- 8) A uterus with short horns and a relatively large body, and a prominent depression in each ovary where the egg cells are released.
- 9) A large, vascular penis and a complete set of male accessory sex glands.

There are similarities between human and equine anatomy, but there are many differences too. For example, the human knee and the equine stifle have a lot in common. The equine radius is similar to the human forearm. Equine carpal (knee) bones compare to human wrist bones. And equine splint bones compare to human fingers.

There is also a similarity in the cooling process during exercise—both humans and horses cool their bodies via sweating. Yet, the two are worlds apart when looking at the digestive process.

Skin

When discussing equine anatomy, what better place to start than with the skin, the horse’s largest organ, ranging from 12-24% of the animal’s total weight depending on age. It serves a number of functions. It protects underlying tissues from injury, drying, water absorption, and bacterial invasion. Another important role involves thermoregulation (regulation of body temperature). The skin also excretes water and

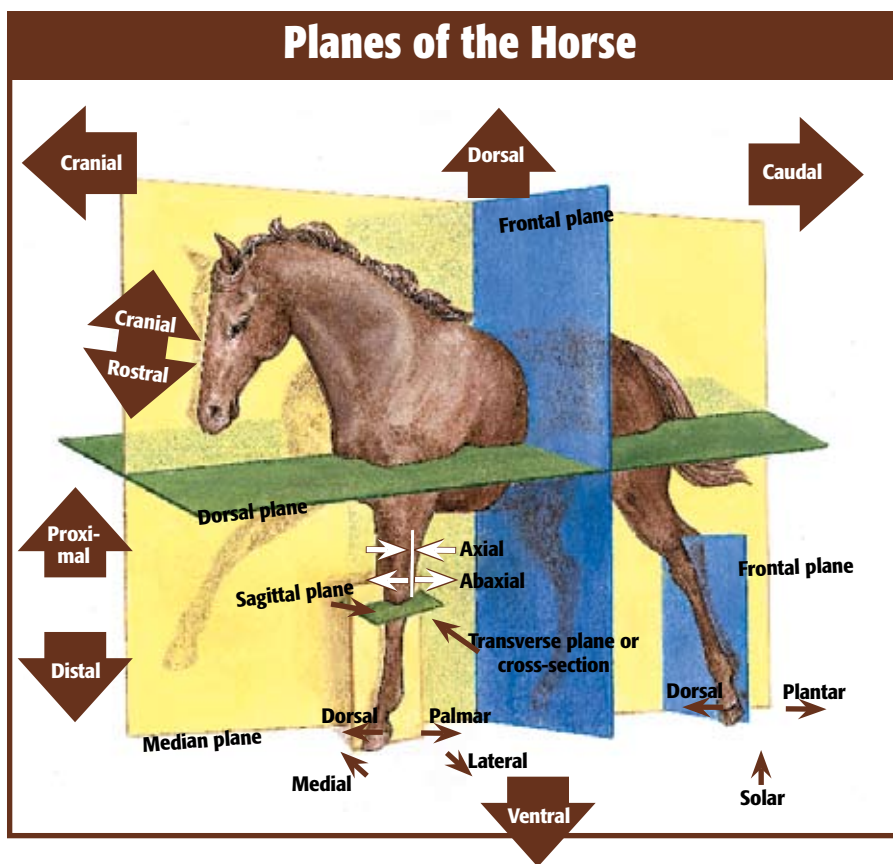
salts through sweat glands, senses the environment, and synthesizes vitamin D in response to sunlight.

The skin consists of various cellular and tissue components. There are two layers, the epidermis and the dermis (subcutis), with the epidermis being the outer layer. The two are attached by collagenous and elastic connective tissue.

The main activity of the epidermis is to produce two types of protein—keratin and melanin. Keratin, the principal component of the epidermis, is a simple protein characterized by its insolubility (it won’t dissolve) and fibrous structure. It serves a supportive and protective function, including the shedding of water. Melanin is the dark, shapeless pigment of the skin and hair.

Another cell type in the epidermis is the Langerhans’ cell, a non-neural cell that is active in the immune response and possibly in the regulation of keratin formation.

The most important part of the epidermis is the superficial layer—known as the stratum corneum—since much of the functional activity of the skin resides here. The proper functioning of this superficial layer is dependent on the structural arrangement of the keratin it contains and on its lipids—fats and fat-like substances characterized by being water-insoluble. Lipids and keratin combine to waterproof the skin and prevent various agents from



entering the body. If this superficial layer of the epidermis were removed, the skin would be like a mucous membrane that is easily permeated by water and a variety of agents.

The hair follicles in a horse's skin are quite simple, with a single hair emerging from each pore. The hair that emerges from these pores serves as frontline protection for the horse. First, a heavier growth in cold weather helps to provide warmth and a lighter coat during summer facilitates the cooling process. The hair also serves as an important filtering system. For example, ultraviolet light is filtered by the hair coat and is absorbed by melanin granules in the epidermis and hair. Hair is composed of keratinized epithelial cells.

Each hair consists of a shaft and a root that is contained in a depression known as the hair follicle. Associated with hair follicles are sebaceous (oil) glands and bundles of smooth muscle connecting the side of the hair to the dermis. The sebaceous glands secrete an oily substance into the follicles and thus to the epidermal surface. The oil lubricates the skin to prevent excessive evaporation that can result in dry skin.

There are two types of sweat glands in the horse—the apocrine and the eccrine glands. The apocrine glands are spread throughout the skin, while the eccrine glands are found only in the frog of the hoof and, thus, play a very limited role in the cooling process. The horse sweats the most of any of the domestic species. The sweat glands are simple, coiled, tubular glands that open independently of the hair follicle.

Nerve endings in the dermis, just under the epidermis, are called sensory nerves and carry sensations of pressure, pain, heat, and cold. In contrast, motor nerves cause the sweat glands to secrete.

When sweat reaches the surface of the skin, it evaporates. This has a cooling effect on the horse's body. Since sweating is the horse's primary method of cooling the body during exercise, cooling can be severely compromised when evaporation of that sweat does not take place, such as on a hot, humid day. Unfortunately, nature didn't provide much in the way of backup measures for hot, humid weather, and it is up to the humans involved to help out by providing plenty of water to drink and cool mists or baths to cool the body when horses must be exercised in such conditions.

Research has shown that a horse's body temperature can rise to a dangerous level

very quickly when adequate cooling does not occur. Without proper cooling, body temperatures during endurance rides, for example, can rise to 106°F (normal temperature is 99.5-101.5°F), and the ultimate result can be heat stroke.

There is more involved in the thermoregulation department than just sweating. An intricate system of blood vessels must first carry heat from the core of the body to the skin so that it can be dissipated via sweating. When heat buildup overpowers the horse's ability to dissipate it, the result can be deadly.

Skin is the horse's largest organ, ranging from 12-24% of the animal's total weight.

The problem develops something like this: As heat accumulates, blood flow to the skin is increased to speed up the transportation of heat from the core of the body to the skin surface. As exercise increases, however, sweat loss leads to dehydration and the loss of plasma water from the bloodstream. This results in a decrease in the volume of blood that is carrying heat to the surface. The result is an increased heart rate as the horse's body desperately tries to make up for the decreased volume of blood. Very quickly, body temperature rises and extreme fatigue sets in.

A problem that afflicts some horses and compromises the thermoregulatory system is anhidrosis or dry coat. Horses with this affliction simply can't sweat. It appears that anhidrosis is climate-specific; the signs are found in areas with a hot, humid climate, such as Florida during the summer.

No one is sure what causes anhidrosis, and there is no effective way to treat it other than to move affected horses to a cooler climate. Often, racehorses that suffer from anhidrosis in Florida will show no signs of the affliction when moved to the cooler Midwest.

The growth and shedding of hair coats follows a definite cyclical pattern. A heavier coat grows when days shorten and weather turns colder, with shorter periods of daylight, and is shed when days become longer and warmer and there are longer periods of light.

Again, we turn to McCracken and Kainer for an explanation of what occurs: "Horses shed hair mostly in the spring, beginning with the belly and sides and continuing up onto the back. The hair cycle includes an actively growing stage (anagen) followed by a stage (catagen) during which the hair matrix sort of shrinks (atrophies) and peels away from its blood supply. A longer, quiescent period (telogen) then occurs in which the hair (club hair) separates from the hair matrix, but remains in the follicle. The matrix later becomes active and begins to grow a new hair that pushes out the old club hair (shedding)."

There are health conditions that can overpower the forces of nature in the shedding department. For example, horses suffering from Cushing's disease often carry a heavy coat even during long-light, hot summer days.

The color of a horse's hair is determined by a rather complicated genetic process involving the amount of pigment in the hair. There are three basic hair pigments—black, brown, and yellow. The great variation in color has to do with combinations or absences of these three pigments.

Skin Problems

The skin, as the first line of defense against the elements, insects, and antigens, is under almost constant attack from one source or another. In many cases, the conditions are not life-threatening, but produce a great deal of irritation to the horse and can lead to more serious consequences.

Here are some of the attackers that make war on the skin:

Dermatitis—This is an inclusive term for inflammation of the skin that can be produced by many agents, such as external irritants; burns; allergens; trauma; bacteria; viral, parasitic or fungal infections; and systemic diseases. When dermatitis surfaces, the important thing is to determine the underlying cause, as treatment can vary a great deal. An example of dermatitis is ringworm, which is actually an infection of keratinized tissue by one of several types of fungi. The most common form of ringworm—which is easily transmitted from animals to humans—produces skin lesions that appear as small rounded spots in the skin. The lesions eventually form blisters and break, leaving scabs in their wake.

Rain Rot—This condition carries the scientific name of dermatophilosis. It is a form of dermatitis that is more common in wet, humid climates than in arid areas. The condition is caused by a fungus that

is capable of creating infection when conditions are right, such as during hot and humid periods. The infection results in scabby spots that are devoid of hair when rubbed free.

Mange—This condition is caused by several species of mites. Mange is characterized by loss of hair, itching, and intense irritation to the skin.

Lice—Horses can harbor two species of lice. One species, *Damalinia equi*, is the horse biting louse and the other, *Haematopinus asini*, is the horse sucking louse. Afflicted horses will show signs of itching by constantly rubbing and biting at affected areas.

Lice are most often found in unthrifty horses and quickly add to the poor condition status. In severe infestations, the horse might lose patches of hair.

Dandruff—This is a condition where the horse's skin becomes scaly and the hair coat often is dry and dirty. In some instances, the hair will fall out. Grooming can help to stimulate the sebaceous glands; exercise and a proper diet can prevent this problem and can work to solve it if it does occur.

Biting Insects—During the summer months, horses are under almost constant attack by one type of biting insect or another, including flies, mosquitoes, and ticks. Not only are these pests irritating to the horse, but they also spread diseases such as West Nile virus, equine infectious anemia, and encephalitis. Responsible horse owners should take all steps that are possible to prevent these disease-carrying pests from attacking the animals in their charge.

Hyperelastosis cutis (HC)—This is an inherited condition of Quarter Horses from a particular bloodline. Earlier, we mentioned that the epidermis and dermis are held together by collagenous material, sort of like glue that can bind two substances. When a horse inherits the genes that cause HC, the collagenous material is defective and unable to hold the two skin layers together;

the result is tearing of the skin, which often results in a death sentence for the horse. There is no known treatment.

Stay Tuned...

There, in short form, is a description of the equine skin and its functions. In upcoming articles, we will concentrate on different parts of the horse's anatomy with an in-depth look at how they are structured, the functions they serve, and what is involved in keeping them healthy.

Here is a brief look at those upcoming article topics, to whet your appetite.

The equine skull houses the brain and the most important organs of sense. There are 34 bones in the equine skull, most of

means that the horse can see objects with one eye. As a result, the brain often gets two images simultaneously. With binocular vision the horse can focus with both eyes and the brain is receiving only one signal. Humans have binocular vision only.

From the equine head, we move to the neck. There are seven cervical vertebrae in the horse's neck, with the spinal cord running through them. The neck blends into the back at the withers.

We come now to the horse's rib structure. Normally, there are 18 pairs of ribs in the horse, but a nineteenth rib on one side or both is not considered all that rare. Eight pairs of ribs are known as true ribs. They join the segments of the sternum or

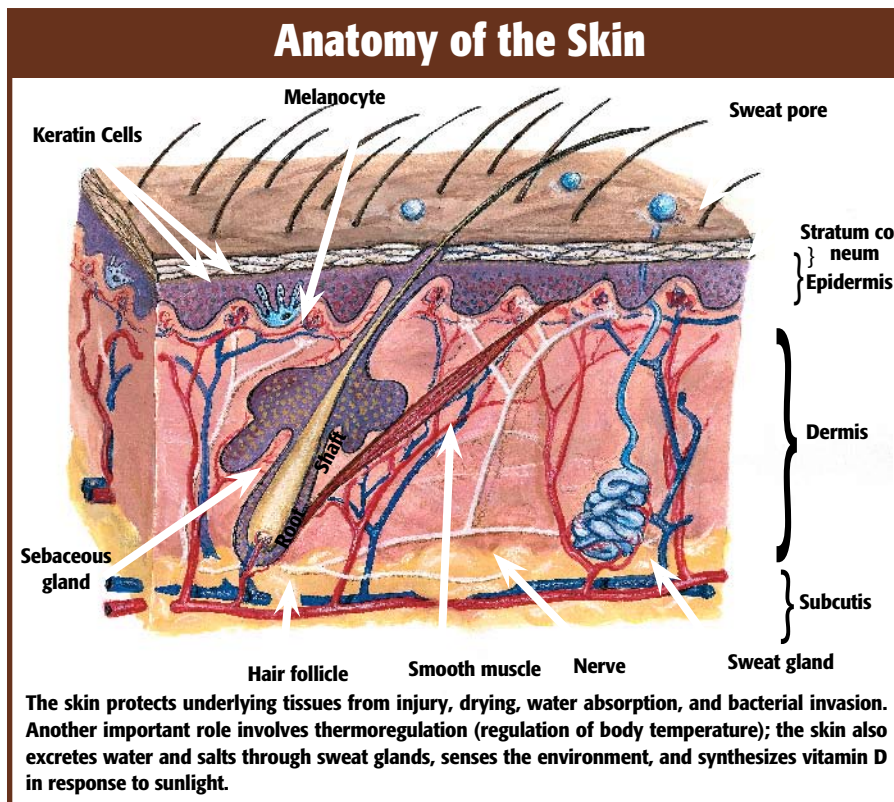
breastbone. The other 10 are known as floating ribs—merely overlapping and being attached to each other. The seventh and eighth ribs are the longest. Those toward the rear are much shorter.

Next we switch to the horse's thoracic or front limbs. Each of these consists of the scapula, humerus, radius, ulna, seven or eight carpal bones, cannon bone, two splint bones, two proximal sesamoid bones, large pastern bone, small pastern bone, navicular bone, and

Horses, donkeys, and zebras are in the mammalian order of odd-toed, hoofed animals (Perissodactyla) as are their distant relatives, rhinoceroses and tapirs.

them flat. During the birthing process, these bones yield and overlap, allowing the skull to be somewhat compressed and thus allowing for easier parturition.

The horse has unique eyes—they are both monocular and binocular. Monocular



DR. ROBIN PETERSON ILLUSTRATION

coffin bone. The structure of these bones and their functional relationship to each other helps determine a horse's athletic potential and its capability of remaining sound even under an exacting exercise and performance regimen.

The angles at which the bones connect have much to do with the horse's physical capability and its continued well being.

The leg bones, as well as other bones, are connected at joints. There are three types of equine joints—synovial, which are movable; cartilaginous, which are slightly movable; and fibrous, which are immovable. The joints that connect the horses' front leg bones are synovial. A synovial joint consists of two bone ends, covered by articular cartilage. The cartilage within the joint is smooth and resilient, allowing for frictionless movement. Ligaments keep the bones in proper support and relationship.

In the rear legs, we'll start at the spine where the ilium, the largest of three bones in the pelvis, connects with the spinal column. The ilium angles down and rearward to blend into the femur or thigh bone. The femur angles slightly forward to the stifle. Beginning at the stifle (comparable to the knee in humans) is the tibia, which continues downward to the hock. From the hock to the pastern is the metatarsus or rear cannon bone, which connects with the long pastern bone; next is the short pastern bone, and lastly the coffin bone. Both front and rear limbs are connected and supported by ligaments, tendons, and muscles that provide attachment and mobility.

Nature didn't do the horse many favors when designing the way in which it processes food. Its stomach can hold only small amounts of food—eight to 16 quarts at a time. The stomach empties into the small intestine, a tube that connects with the large intestine. The small intestine is approximately 70 feet long, with a capacity of about 12 gallons. The large intestine of the horse is divided into four parts—the cecum, which is about four feet long and one foot wide; the great colon, which is about 12 feet long and 10 inches wide; the small colon, which is about 10 feet long and four inches wide; and the rectum.

In the reproductive department, the main sex organs of the mare are two ovaries that produce eggs, which are housed in follicles. When an egg is mature, it leaves the follicle and travels through the infundibulum and oviduct to the uterus. If fertilized, it grows within the uterus from a minute structure into a foal that is born through the vagina.

The primary sex organs of the stallion are the two testicles, which produce semen and testosterone, and the penis.

A horse's respiratory system is designed—as is the case with other mammals—to exchange oxygen and carbon dioxide. Air enters the nostrils, passes through the long nasal cavity over the pharynx and larynx, then enters the trachea that carries it to the lungs.

A horse's cardiovascular system consists of blood, a series of blood vessels through which blood flows, and a heart that pumps blood throughout the horse's body. Blood is comprised of red blood cells, white blood

cells, and platelets. The red blood cells have a protein known as hemoglobin that binds oxygen and conveys it to the muscles. The white blood cells function in the immune system by defending against foreign invaders, such as harmful bacteria, and the platelets are involved with blood clotting. 🐾

ABOUT THE AUTHOR

Les Sellnow is a free-lance writer based near Riverton, Wyo. He specializes in articles on equine research, and he operates a ranch where he raises horses and livestock. He has authored several fiction and non-fiction books, including Understanding Equine Lameness, Understanding The Young Horse, and The Journey of the Western Horse, published by Eclipse Press and available at www.ExclusivelyEquine.com or by calling 800/582-5604.

Required Reading for Responsible Horse Owners.



For over 10 years *The Horse: Your Guide to Equine Health Care* has been essential reading by responsible horse owners.

Subscribe today, and along with your full access to TheHorse.com, you'll receive 12 issues of *The Horse* filled with essential information you need to know to keep your horses healthy and strong. Order now and **SAVE OVER 72%** off the cover price. Plus, you'll get the next edition of *The Horse Source* FREE.



NO RISK. NO OBLIGATION.

Your satisfaction is absolutely guaranteed. If you're not completely satisfied, we'll send you a refund for all unmailed issues!



SUBSCRIBE NOW!

CLICK HERE or
call 1-800-582-5604

the **HORSE**
YOUR GUIDE TO EQUINE HEALTH CARE

CQ06Z23

IT ALL Hinges On This



There are 205 bones in the horse's skeleton. Twenty of these bones are in each foreleg and 20 in each hind limb, for a grand total of 80 bones in the four equine legs. The leg bones do not function independently. Each is connected or aligned with one or more other bones, allowing the horse to lift, bend, and flex its legs. This ability allows the horse to travel across the ground, absorbing concussion as it does so. The spot where one or more bones join is the joint. This installment of the anatomy and physiology series focuses on these critical areas of movement.

Types of Joints

There are three types or classifications of equine joints. They are:

Synovial joints—These are the movable joints and the ones most apt to sustain injury or be afflicted with disease. An example of a synovial joint is the carpus (knee), which actually contains three joints and multiple bones. In a manner of speaking, the synovial joints are the horse's ball bearings. A synovial joint consists of two bone ends that are both covered by articular cartilage. The cartilage within the joint is smooth and resilient, allowing for frictionless movement. Each joint capsule also contains an inner lining called the synovial membrane, which secretes synovial fluid to lubricate the joints.

*Proper movement
of the horse is
dependent on proper
functioning of his joints*

Cartilaginous joints—These joints are slightly movable or immovable, depending on the bones involved. Cartilaginous joints are united by fibrocartilage (composed of collagen fibers), hyaline cartilage (translucent bluish white), or both. An example is the connective tissue between vertebrae.

Fibrous joints—These are immovable joints where the bones are bound by fibrous tissue that ossifies (hardens into bone) as the horse matures. An example would be joints within the equine skull.

We'll concentrate on synovial joints because they are the most active and are more prone to problems than joints with little or no movement.

As in the opening article of this series in January, we will point out that information for this article is drawn from many textbooks and scientific papers that have been

Editor's Note

This is the second in a 12-part series of articles on equine anatomy and physiology. Future topics include the foreleg, the hind limb, the hoof, the head and neck, the back, muscles, tendons and ligaments, the digestive system, the circulatory and respiratory systems, and the reproductive system.

DR. ROBIN PETERSON ILLUSTRATIONS



published. However, we would be remiss in not calling attention to the three key sources for the information that follows. One is *Anatomy of Domestic Animals*, a textbook authored by Chris Pasquini, DVM, MS, and Tom Spurgeon, PhD, of the Department of Anatomy and Neurobiology at Colorado State University.

Two other key sources are C. Wayne McIlwraith, BVSc, PhD, MS, MRCVS, Director of Orthopaedic Research at the College of Veterinary Medicine and Biomedical Sciences at Colorado State University, and Jerry Black, DVM, a California veterinarian. Both are past presidents of the American Association of Equine Practitioners (AAEP) and both have lectured on the subject of joints and joint problems in horses. Information for this treatise has been taken from interviews and from presentations they have made at AAEP conventions and, in Black's case, Horseman's Day, an owner education event sponsored by AAEP.

First we'll look at how synovial joints are constructed, then we'll outline where they are located, the functions they serve, and some of the problems that can develop.

How It Works

The joint structure is designed to absorb concussion and permit leg movement. The two bone ends are encased in a fibrous capsule that helps provide stability. Collateral ligaments, comprised of very tough fibers, attach to the sides of each of the bones within the capsule, and this plays a major stabilizing role. Other ligaments, such as the cruciate ligaments, also help stabilize some joints, including the stifle. Other ligaments outside the joint cavity also lend support. A prime example would be the distal sesamoidean ligaments and suspensory ligaments that, together with the sesamoid bones, make up the apparatus that holds the fetlock in proper position.

The outer part of the joint capsule is the fibrous layer and the inner part is synovial membrane that lines the sides of the joint capsule. The joint is lubricated by synovial fluid, which is secreted by the synovial membrane. The ends of each of the bones

within the fibrous capsule are covered with cartilage, which primarily is hyaline cartilage—a substance that is flexible and somewhat elastic. Beneath the cartilage in each bone end is subchondral bone.

We mentioned earlier that the synovial membrane secretes lubricating fluid that allows a healthy joint to have frictionless movement. In addition to being a lubricant, synovial fluid also supplies nutrients and removes waste from hyaline articular cartilage. Synovial fluid is described as having the consistency of raw egg white.

An important component in the makeup of synovial fluid is hyaluronic acid, also known as sodium hyaluronate or hyaluronan. It is primarily responsible for giving the synovial fluid its lubricating capability. When disease strikes a joint, there often is a depletion of hyaluronic acid. When that happens, the joint's ability to function

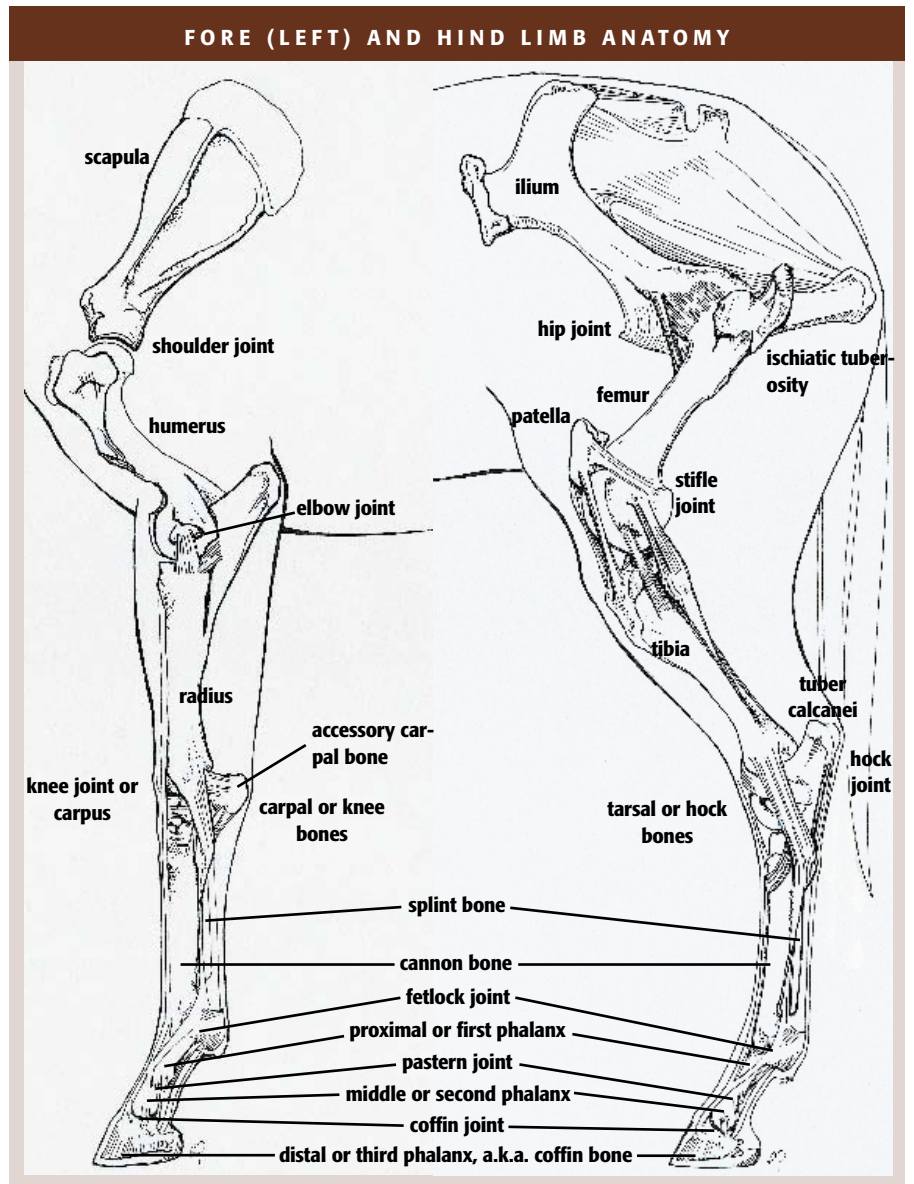
properly—for movement and as a concussion absorber—is compromised.

There is a second method for lubricating cartilage in a joint. Fluid is stored within the cartilage and when weight bearing occurs, it is squeezed out of the cartilage onto the surface. When weight bearing ceases, the fluid is reabsorbed by the cartilage.

The Front Limb

Injury and disease to the front limb joints are more common than injury to the rear limbs. Why? A horse carries 60-65% of its weight on the front end. This means that the joints of the front limbs are subjected to a greater share of the concussion with each step the horse takes than are the rear limbs, especially during strenuous activities such as racing and jumping.

For the most part, construction of equine synovial joints is a wonder of



nature, but there are exceptions. A key exception is the knee, which almost seems to have been constructed haphazardly. There are eight bones in the horse's knee and three main joints to keep them all aligned and functioning properly, which is no small task. The eight bones are arranged in two rows.

The three prime knee joints are located thusly: One between the radius and proximal (upper) row of four carpal bones; one between the two rows of carpal bones (usually there are four bones per row), and one between the distal (lower) row of carpal bones and the cannon and splint bones.

There also are tiny joints between the individual carpal bones.

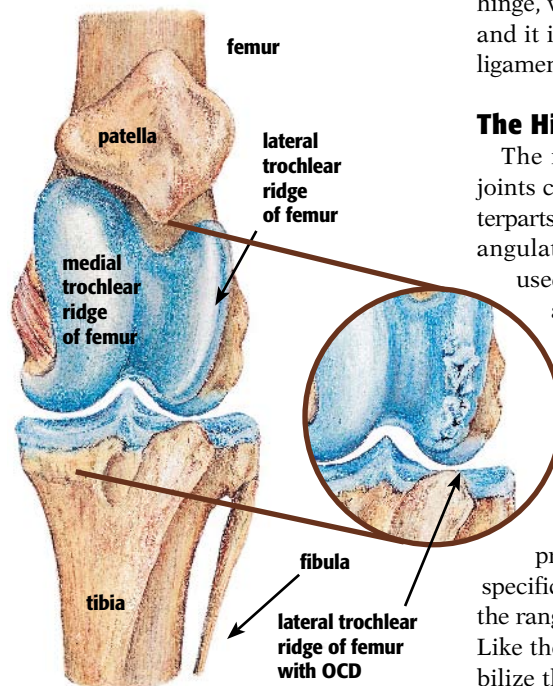
Because the knee is structured with multiple bones, it becomes immediately apparent that good conformation is a prime requisite in keeping this joint healthy and strong. Any deviation, such as being over or under at the knee, puts undue stress on the complicated knee joint and opens the door for a multitude of potential problems.

From the knee on down, the joint structure is slightly less complicated. The cannon bone continues downward from the knee until it joins the long pastern bone, or first phalanx (P1), at the fetlock joint. Also located at this junction are the medial and lateral proximal sesamoid bones. These bones are deeply imbedded in, and are supported by, the suspensory ligament. They are subject to injury and fracture, particularly if the horse interferes and strikes them with the opposing limb.

It is amazing that more racehorses and jumpers don't break down at the fetlock joint. To understand that statement, we must realize that when a racehorse runs at top speed, there is one point in every stride where its entire weight descends upon one front leg, with most of the concussion being absorbed and dissipated by the fetlock joint. The force of that concussion often drastically changes the angle of the fetlock. At rest, the fetlock generally is at an angle of about 50°. When all of the weight comes to bear on that one leg when a horse runs at speed, the fetlock is often almost level with the ground, or at zero degrees, placing tremendous stress on the fetlock joint.

The next joint below the fetlock is the pastern joint. This is where P1 connects with the short pastern bone, or second phalanx (P2). This joint moves very little and does not absorb a great deal of concussion when compared to the fetlock joint.

LEFT STIFLE JOINT: NORMAL AND WITH OCD



Osteochondrosis might lead to OCD or subchondral cystic lesions. OCD normally shows up in one joint rather than multiple joints. However, bilateral involvement (of both front or hind limbs) is sufficiently common that the opposite joints should always be radiographed.

We are now down into the foot where joints also play connecting and shock absorbing roles. The coffin joint is next in line as we travel downward, and it connects P2 with P3 (the coffin bone). This is a movable joint that plays a very important role in absorbing concussion.

Helping in the weight-transferring and shock absorbing roles at this location is the navicular bone, which is supported by the deep digital flexor tendon. The deep flexor tendon is closely fitted to the surface of the navicular bone with a navicular bursa, a fluid-filled sac that provides a smooth, lubricating substance that reduces friction.

Again, we can't get away from the importance of good conformation when considering the health and maintenance of these joints. When any of these joints are out of alignment, there is a great deal more stress on them, especially when the horse is exercising vigorously.

There are two other joints—shoulder joint and elbow joint—in the forelimbs, but they don't absorb much concussion because the concussion already has been absorbed and dissipated by the other joints as the first line of defense. The shoulder joint is a hinge joint that is held in place

by a strong web of ligaments, muscles, and tendons. The elbow joint also works like a hinge, with movement on only one plane, and it is stabilized by medial and lateral ligaments.

The Hind Limb

The rear fetlock, pastern, and coffin joints correspond to their front leg counterparts, although they usually have steeper angulations because the back limbs are used more for propulsion than shock absorption.

Two additional joints in the rear end deserve discussion because they are highly important in the horse's ability to perform properly. They are the hock joint and the stifle joint. The hock joint is a bit like the knee in that it is comprised of multiple bones—six, to be specific. However, these bones don't have the range of movement of the knee bones. Like the knee joint, strong ligaments stabilize the hock joint and facilitate movement.

The stifle joint has to be considered one of the key joints in the equine body. It is similar to the human knee, and when it becomes injured or diseased, the horse's ability to move can be severely compromised.

The stifle is the largest single joint in the horse. One of its functions is to cause the rear limb to become rigid when the foot is on the ground. This is controlled via contraction of muscles above the patella, which releases the stay apparatus, and is the equivalent of a human's kneecap.

Once again, we must call attention to the role of good conformation in keeping these key joints healthy. Deviations—such as being too narrow or too wide at the hocks—can result in undue stress, which can lead to a variety of hock joint problems.

A clear example of a ball and joint socket is the hip joint. The head, or upper end, of the femur fits into the socket formed by the hip. The hip joint is stabilized by a strong band of ligaments. One of the ligaments stabilizing the hip joint is the accessory ligament, which does not occur in any domestic animal other than the horse.

Common Problems

All of the synovial joints are subject to injury or disease as the result of poor conformation or the ongoing wear and tear of heavy performance demands placed on the animal by its rider.



These conditions are categorized as follows:

Synovitis—Inflammation of the delicate synovial membranes.

Capsulitis—Inflammation of the fibrous joint capsule. This condition usually is present when synovitis occurs.

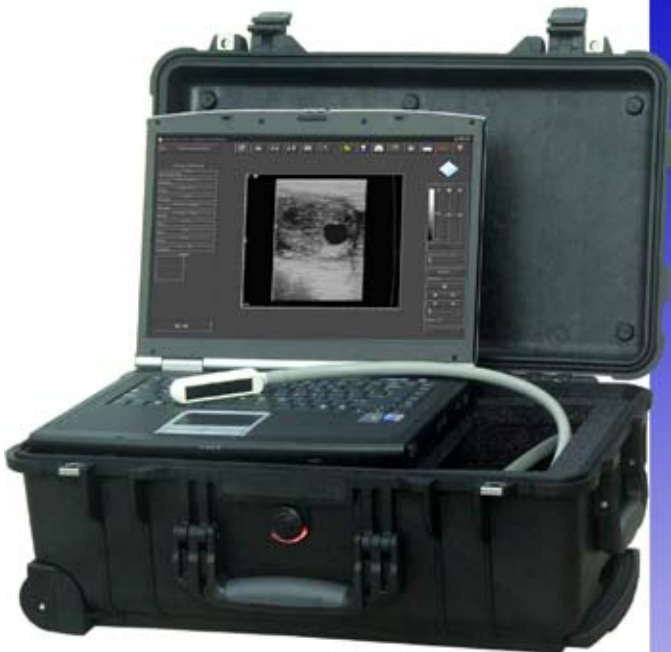Osteoarthritis—The result of severe joint injuries and of injuries that are not treated adequately. Its signs include swelling and pain, plus the progressive loss of articular cartilage on the surface of the bone. This is a permanent condition that can render the horse unsound and unusable.

Others problems can include bone fragmentation or fracture in a joint and tearing of the ligaments that stabilize the joints.

Varying disciplines can produce different joint problems. For example, horses used for jumping will tend to have more problems in front leg joints, and horses used for cutting and reining will tend to have rear leg joint problems. Both will have more of a tendency for joint problems than the trail horse or even the endurance horse. The reason is that the joints are designed for straight-line movement and not for the concussive trauma of landing after a high jump or the torque delivered to hock and pastern joints from a sliding stop or spin.

With joint injury, there is inflammation that can stimulate the release of problem agents called free radicals, prostaglandins, and cytokines. These agents attack the basic components of articular cartilage and set in motion a degenerative process that can quickly compromise a horse's ability to perform if untreated. In the process, there often is a depletion of hyaluronic acid that might have to be replenished either via direct injection into the joint or intravenously.

*Experience the Evolution....
Computer Ultrasound for the Digital Office*



Digital Image Capture
Easy to Use Interface
High Quality Images
Easy to Add Programs

Classic Medical
Since 1985
Classic Digital IMAGING

Notebook Ultrasound

When a joint is puffy and sore, this means joint damage or disease is present.

When a joint is puffy and sore, this means joint damage or disease is present. A veterinarian should be summoned so that the proper treatment can begin immediately. Often a first-line treatment of choice is the application of ice to the injured joint in an effort to immediately reduce inflammation.

Take-Home Message

The movement of a horse is dependent on joints of various types. Proper conformation is a good deterrent to joint problems, but injury or stress from repeated or hard exercise can cause damage to joints. Unless they are diagnosed and treated early, these problems can cripple the horse and end his athletic career. 🐾

ABOUT THE AUTHOR

Les Sellnow is a free-lance writer based near Riverton, Wyo. He specializes in articles on equine research, and he operates a ranch where he raises horses and livestock. He has authored several fiction and non-fiction books, including Understanding Equine Lameness, Understanding The Young Horse, and The Journey of the Western Horse, published by Eclipse Press and available at www.ExclusivelyEquine.com or by calling 800/582-5604.

19900 Mona Road, #105 • Tequesta, Florida 33469
(800) 722-6838 • (561) 746-9527 • info@classicmed.com
www.classicmedical.com

On the FOREHAND

BY LES SELNOW

The foreleg of the horse is, for the most part, a model of good engineering. It is structured in such a fashion that the horse can move slowly or at speed with the concussion of each footfall minimized by a sophisticated shock absorbing system.

Most of a horse's weight is carried on its forelimbs. Good conformation will help ensure long-term soundness

The system works very well when the horse is doing what nature intended—wandering about over large expanses, grazing, drinking, breeding, and resting. But today's horse often soars over multiple six-foot jumps, runs at speed for a mile or more around an oval course, slides to a stop suddenly and spins, or performs intricate dressage movements.

These disciplines often put undue stress on the legs that can render even a well-conformed horse unsound. A horse with improper conformation is at much greater risk for unsoundness when competing

Editor's Note

This is the third in a 12-part series of articles on equine anatomy and physiology. Future topics include the the hind limb, the hoof, the head and neck, the back, muscles, tendons and ligaments, the digestive system, the circulatory and respiratory systems, and the reproductive system.

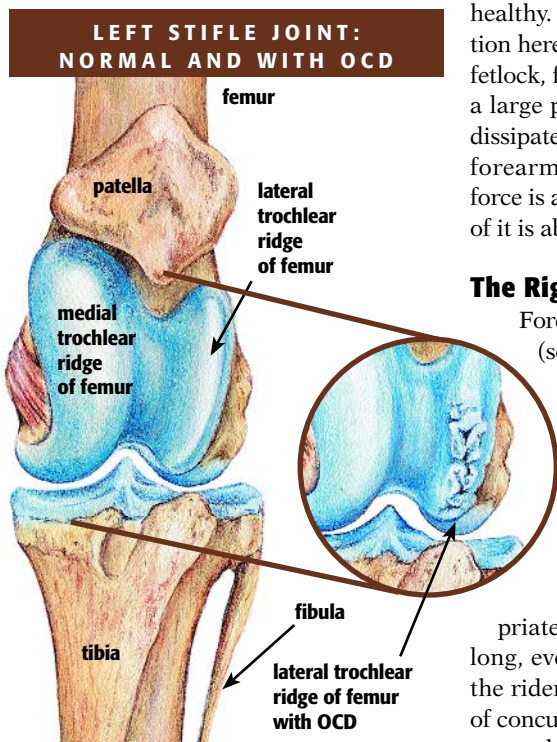


DR. ROBIN PETERSON ILLUSTRATIONS



disciplines. This doesn't mean a horse with poor conformation will always become unsound or lame. What it does mean is that poor conformation is a warning sign that something might go awry.

It also should be noted that a horse puts more stress on its front legs than its rear limbs because it carries 60-65% of its weight up front. It seems incredible that when a horse is running at speed, there is a split second in every stride where all of the animal's weight, plus the additional impact involved when running all out, lands on one front leg.



Osteochondrosis might lead to OCD or subchondral cystic lesions. OCD normally shows up in one joint rather than multiple joints. However, bilateral involvement (of both front or hind limbs) is sufficiently common that the opposite joints should always be radiographed.

We will take an in-depth look at just how the forelimb is constructed, what constitutes good conformation, and what can go awry when poor conformation is involved.

The information presented comes from many sources. A key source for

researchers, veterinarians, and horse owners in the study of equine limbs is the late O.R. Adams' book *Lameness In Horses*.

No Connections? Shocking!

An interesting aspect of front limb construction in the horse is that the front legs are not connected to the rest of the skeleton. If one were so inclined, one could amputate the entire front leg—from scapula (shoulder blade) on down—without the scalpel ever touching bone. Instead of bone and joints, the horse's front legs are connected to its body by a network of muscles, ligaments, and tendons. Basically, the horse's front legs help form a sling that supports the front part of the animal's body.

A prime purpose of the front leg is to serve as a shock absorber. If the impact of each stride were transmitted upward in a straight line, joints, muscles, tendons, and perhaps even bones would not remain healthy. The key to proper shock absorption here is angle. The proper angle of the fetlock, for example, makes it possible for a large portion of the shock forces to be dissipated before traveling up to the knee, forearm, and shoulder. The rest of the force is absorbed along the way, but much of it is absorbed at the fetlock level.

The Right Angles

Forelimb angles begin at the shoulder (see illustration at right). If the animal has good conformation, the shoulder will be angled back at an appropriate degree. Just exactly what that "appropriate" degree is will vary from horse to horse, but the angle is key to the horse's stride.

If the shoulder is aligned appropriately, the horse will step out with a long, even stride that is comfortable for the rider and produces the least amount of concussion. But if the shoulder angle is steep, the horse's stride will be short and choppy. This will make for an uncomfortable ride, but worst of all, it means the front feet will hit the ground more often over a prescribed course and each time they do, the force of concussion will be greater than for a horse with a properly angled shoulder. This is because the shoulder angle dictates other angles involved in dissipation of concussion.

For example, a straight shoulder normally means a horse will have a straight or upright pastern. The straighter the pastern, the less shock absorbed during each stride.

Dem Bones

Let's look at each of the forelimb bones, traveling from top to bottom. We start with the shoulder bone or scapula. This is a broad bone that connects to the next in line—the humerus, which is analogous to the human upper arm bone. This bone angles down and rearward until it joins up with the radius (forearm) at the elbow. The radius extends downward to the knee or carpus, which compares to the human wrist. One can almost liken the many little bones of the knee to building blocks arranged in two rows. The radius connects at the upper portion of this structure and the metacarpus (cannon bone) connects to the lower or distal aspect. The cannon bone extends downward to the pastern.

The fetlock joint connects the cannon with the first of three pastern bones. The first pastern bone is known as the first phalanx or P1. It fits into the second pastern bone via the pastern joint, with the second bone known as the second phalanx or P2. The second phalanx fits into the third phalanx (P3 or coffin bone) at the coffin joint. The coffin bone is housed completely within the hoof capsule.

While the above could be described as the key bones in the front limb, others serve equally important functions. For example, just behind the cannon bone, where it joins the long pastern bone, are two proximal sesamoid bones. They serve as pulleys for the flexor tendons as the tendons bend around the fetlock joint; these tendons help flex the legs and generate propulsion.

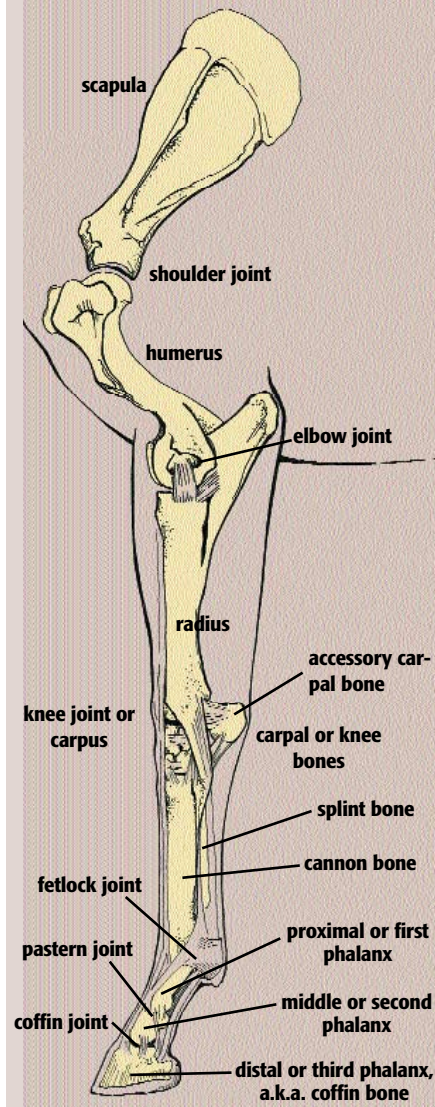
Another bone completely encapsulated by the hoof is the distal sesamoid bone, more commonly called the navicular bone. It is located at the junction of the short pastern bone and the coffin bone and provides another pulley-type surface for the deep digital flexor tendon as it angles towards its end on the bottom of the coffin bone.

Two other bones in the front leg must be mentioned—the splint bones that extend downward from the knee. Known as the second and fourth metacarpal (front legs) or metatarsal (hind legs) bones, these help support the cannon bones. Most authorities speculate they are evolutionary remnants from the prehistoric three-toed horse. Splint bones can be fractured or broken, causing pain and unsightly blemishes.

Good, Bad, and Ugly

We have mentioned "good" conformation and "bad" conformation several times in this article. Let's define just what is

FORELIMB ANATOMY



meant by those terms. To do that, we must examine a front leg from at least two vantage points—from the front and from the side.

First, we stand in front of the horse and look at the front leg. In our mind's eye, we will superimpose a vertical line that travels in a straight path from the point of the shoulder down through the middle of the forearm, through the middle of the knee, and down the center of the cannon bone, fetlock, and hoof.

The purpose of superimposing this line is to determine how much deviation there is to one side or the other. If, when we study our superimposed line, we find that it truly does run through the center of the limb, we likely have a horse with the basics of good forelimb conformation.

But what if it doesn't? What are we dealing with? Let's look at some of these con-

ditions and what they might mean, noting as we do so that few, if any, horses have perfect forelimb conformation:

Toeing Out—If this is the case, the horse's front feet will literally be pointed outward and our superimposed line will run down through the inside or medial aspect of the foot. These horses will put extra stress on the inside of the knees and fetlocks with every stride. Of course, stress increases when the horse travels at speed or lands after a jump. In addition, as the horse travels, it will tend to wing inward with each foot during each stride, particularly at the trot. When this is the case, the horse is in danger of striking the sesamoid and splint bones of the opposing limb.

Toeing In—As the name implies, this is the direct opposite of toeing out, and it often has less severe consequences. A toed-in horse often will paddle, which means the feet rotate outward or laterally as it travels, especially at the trot. This is a waste of energy and means the horse does not travel forward efficiently. Its danger of self-injury is limited, but this defect does cause additional strain on the ligaments of the fetlock and pastern joints; problems such as ringbone and sidebone can result. In this case, when examining the leg from in front, the bulk of the foot will be inside or at the medial aspect of our superimposed line.

Bench knee—In these horses, the forearm enters the knee on the medial side and the cannon bone exits the knee on the lateral side, so they don't line up. They are believed to be prone to knee injuries or problems, especially if exposed to stressful competition. However, some studies have found that mildly affected racing Thoroughbreds can do quite well, depending on what other conformational problems are present.

Base-wide—These horses stand with their hooves farther apart than the legs are at the chest. They often have narrow chests, toe out, wing in, and excessively wear the inner side of the foot.

Base-narrow—These animals stand with their hooves closer together than the legs are at the chest. They usually have wide chests, toe in, paddle out, and wear the outside of the foot lower than the inside.

Carpal valgus—Also called knock knees, this angular limb deformity occurs when one or both carpi (knees) deviate medially (inward) when viewed from the front. If left uncorrected, this results in a great deal of stress placed on the ligaments and small bones of the knee, especially on its medial or inner side. Toeing out often accompanies this problem.

Carpus varus—Also called bow legs, this occurs when one or both knees deviates laterally, or outward, when viewed from the front. Abnormally high stresses on the lateral or outer side result from this problem, and toeing in often is also present.

The last two problems occur commonly in foals, but are usually easily corrected either with rest and trimming/shoeing or surgery while the limbs are still growing.

These are seven basic conformational faults that can be observed when viewing the leg from the front. Sometimes they are combined with other conformational faults of the front limb, and that increases the potential for lameness problems.

Now, let's step to the side and look at that same front limb. Again, we will superimpose, in our mind's eye, a vertical line that runs down the center of the limb perpendicular to the ground, reaching the ground just behind the heel. Here are some poor conformations that might be observed:

Calf knee—Horse owners familiar with cattle can easily envision this condition. It also is referred to as "behind at the knee." The knee appears to bend backward from our superimposed line when viewed from the side. These knees place a great deal of stress on ligaments and tendons as well as on the knee joint. A calf-kneed horse would be poorly suited for jumping or racing.

Buck knee—Also called "over at the knee," this is the opposite of calf knee. When viewed from the side, the knee protrudes over our line as if it is always bent to some degree. It isn't as severe as calf knee, but is a definite fault that will put excess stress on joints, ligaments, and tendons.

Standing under—In this conformation, the entire forelimb from elbow on down is consistently placed back too far under the body, behind our superimposed line. Overloading of the front limbs and more frequent stumbling result.

Camped in front—This is the opposite of standing under, with the forelimb from the body to the ground being consistently placed too far forward—in front of the superimposed line. It often occurs with bilateral navicular disease and laminitis.

Short, upright pasterns—In this condition, there is little or no angle to the pastern, which means little dissipation of concussion as the horse travels.

Long, sloping pasterns—This can be a severe problem if the pasterns are so long, sloping, and weak that the fetlock strikes the ground as the horse travels. Neither pastern fault is unique to the forelimbs; they can occur in the hind limbs as well.

is balance, with all parts flowing smoothly together so that there is both appropriate propulsion and adequate shock absorption.

Since no horse has perfect conformation, it is necessary to rely on experts to determine which conformation is best suited to a particular discipline or use. This will enable us to select horses that are more successful and sounder in their careers,

and cause fewer lameness problems for the owner. 🐾

ABOUT THE AUTHOR

Les Sellnow is a free-lance writer based near Riverton, Wyo. He specializes in articles on equine research, and he operates a ranch where he raises horses and livestock. He has authored several fiction and non-fiction books, including Understanding Equine Lameness, Understanding The Young Horse, and The Journey of the Western Horse, published by Eclipse Press and available at www.ExclusivelyEquine.com or by calling 800/582-5604.

Take-Home Message

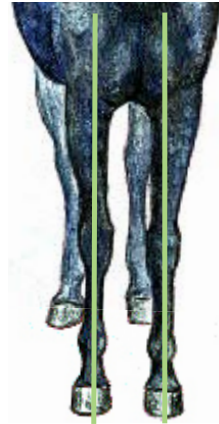The key to good front limb conformation

FORELIMB CONFORMATION PROBLEMS

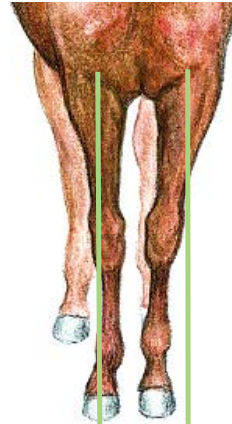Much as we would like to believe otherwise, it is very rare to find a perfectly conformed horse. Most have at least one deviation from what is considered "ideal" conformation, and many have two or more. Horses can still be successful riding or working horses with most of these abnormalities if they are not very severe. This depends on the particular problem and the horse's intended use.

When viewed from either the front or the side, a line bisecting the horse's limb should be straight. Here, the green lines show the angles of the horses' bones with normal conformation and various problems.

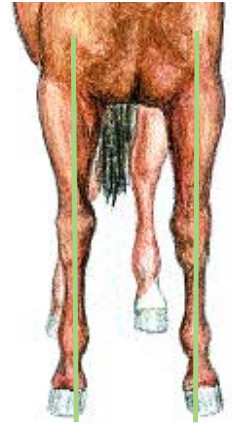NORMAL FRONT END



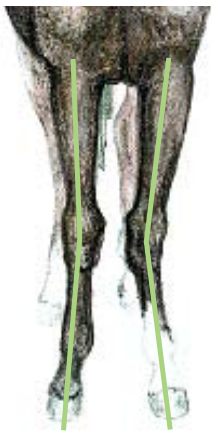BASE NARROW



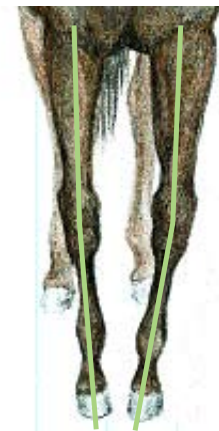BASE WIDE



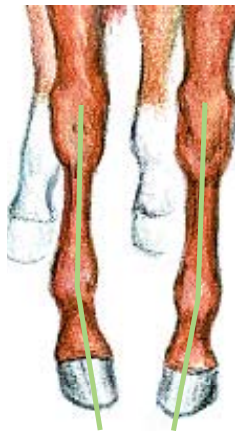KNOCK KNEES



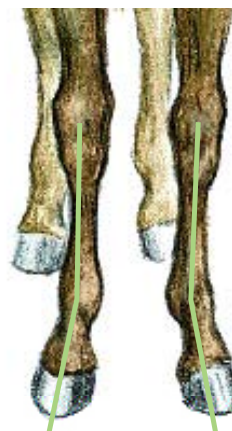
BOW LEGS



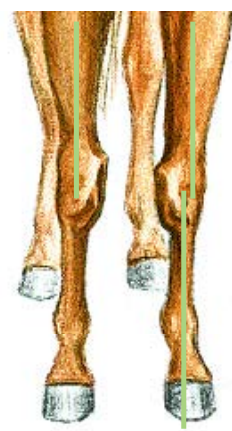TOED IN



TOED OUT



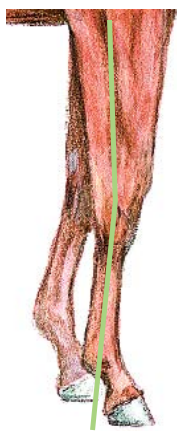BENCH KNEE



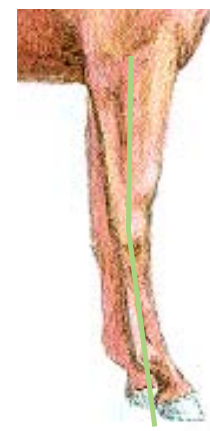
NORMAL FRONT END



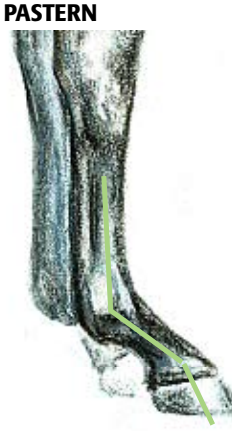BUCKED KNEE



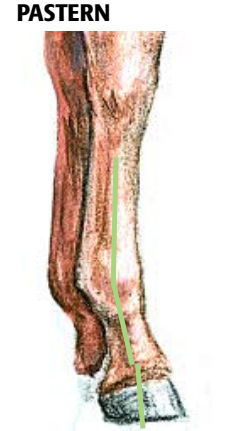CALF KNEE



LONG, WEAK PASTERNS



SHORT, UPRIGHT PASTERNS



THE Perfect Engine

No matter the breed or discipline, good conformation of the hind legs will contribute to more successful performance and a better ride

BY LES SELLOW

Much has already been stated in this series about the special concerns involving front limb soundness in the horse since 60-65% of the animal's weight is carried in the front end. This does not mean that there are no concerns involving the back legs. Far from it. We can think of equine rear end function in terms of cars and trucks with rear wheel drive. The engine, comprised of muscles fueled by heart and lungs, provides the power, and the back legs are akin to piston-driven rear wheels.

The pressure and torque placed on the "rear wheels" varies with the discipline involved. When walking or jogging across the countryside during a trail ride, the stresses are light and easily handled by a horse with normal back leg conformation.

Editor's Note

This is the fourth in a 12-part series of articles on equine anatomy and physiology. Future topics include the hoof, the head and neck, the back, muscles, tendons and ligaments, the digestive system, the circulatory and respiratory systems, and the reproductive system.

DR. ROBIN PETERSON ILLUSTRATIONS



However, if the discipline happens to be cutting or reining with the Western horse or dressage or five-gaited action with the show horse, it is an entirely different matter. Although different in nature, these four disciplines all put high demands on the horse's rear end.

It should also be remembered that, in addition to being the prime source of propulsion, the back legs also serve as the horse's brakes. Again, the stress put on those brakes varies with the discipline. It is vastly different, for example, in a reining horse than it is for one competing in dressage.

We'll take a look at how Nature has designed the rear portion of the horse's anatomy, especially the leg, in an effort to understand why the animal can do what it does. We also will take a look at some of the problems that can develop in improperly conformed legs as a result of these stresses.

An excellent source on equine anatomy as it pertains to feet and legs is the fourth edition of *Adams' Lameness in Horses*, edited by Ted Stashak, DVM, MS, and featuring seven experts in the field as contributors.

Start at the Top

We will begin our visual dissection of the posterior portion of the horse's anatomy at the top, or spine, and work our way downward. Connecting to the spine is the ilium, the largest of three bones in the animal's pelvis. The ilium angles down and rearward, and it attaches to the femur or thigh bone. The angular shape of the pelvis determines what type of croup the horse has—flat or sloped.

The femur angles slightly forward and connects with the stifle, forming one of the more important joints in the rear leg apparatus. Connecting at the stifle joint, as we continue our journey downward or distally, is the tibia, which connects with the hock. Emerging from the distal portion of the hock is the metatarsus or rear cannon bone. This bone continues downward until it connects with the long pastern bone, which connects with the coffin bone. As with the foreleg discussion (see www.TheHorse.com.aspx?id=6623), there are several small bones in the lower hind limb

NORMAL AND PROBLEMATIC HIND LIMB CONFORMATION		
<p>When a horse's hind limbs aren't aligned as they should be, some internal structures are stressed more heavily, resulting in a greater risk of pain and lameness. For example, the cow-hocked horse will place extra strain in the medial side (inside) of his hocks, resulting in a greater risk of bone spavin, and straight hocks will not be able to absorb as much shock as they should.</p>	<p>NORMAL HIND END</p>	<p>NORMAL HIND END</p>
<p>STRAIGHT HOCKS</p>	<p>COW HOCKS</p>	<p>BOW HOCKS</p>
<p>SICKLE HOCKS</p>	<p>BASE-WIDE</p>	<p>BASE-NARROW</p>

that are important to the function of the leg. Where the cannon bone joins the long pastern bone, two small bones—the proximal sesamoids—lie on the back side of the cannon bone and act as pulleys for the flexor tendons. And where the short pastern and coffin bone join, a distal sesamoid bone, or navicular bone, acts in the same manner.

Where Does it Hurt?

The two key places where rear leg lameness problems are apt to develop are the stifle and the hock. Both play key roles in

the horse's ability to propel itself forward, brake to a halt, and move backward.

If one were to rate them as to importance in this regard, the hock would perhaps be placed at the head of the list. The propelling force is transmitted by tendons passing over the hocks, delivering energy from the muscles for forward propulsion. On the other hand, the stifle serves much the same function as the human knee.

As mentioned earlier, the hock, or tarsal joint, is where the tibia joins with the metatarsal bone. The hock is a like the horse's

knee on the front leg in that it is comprised of a number of bones—six to be exact. A difference between hock and knee is the fact that the hock bones lack the degree of motion noted in the bones of the knee. Like the knee joint, the hock joint is held together by a complex set of ligaments that enable it to function. The prime function of the hock is to provide rear leg propulsion.

The bones of the hock include: Calcaneus and talus on top of the central tarsal bone, third tarsal bone, first and second tarsal bones (which are fused), and the fourth tarsal bone.

The horse's stifle joint is the largest single joint in its body. One of its functions is to cause the rear limb to become rigid when the foot is on the ground. This is controlled via contraction of muscles above the patella, which releases the stay apparatus, and is the equivalent of a human's kneecap.

The type of activity with which the horse is involved has a great deal to do with the stresses and pressures that are placed on the hocks. Walking, jogging, or even galloping puts little undue stress on the back legs in general and the hocks in particular.

However, when one ups the ante with some activities, it all changes. One type of stress, for example, is placed on the hocks by five-gaited horses, particularly Saddlebreds. When performing at the signature gaits of rack and slow gait, the horse is moving in a four-beat rhythm. This means that each leg strikes the ground separately. Put another way, it means that all of the horse's weight is balanced on one leg during each complete stride. Add to this the fact that five-gaited horses shift weight to the rear and elevate the front end while slow gaiting and racking, and one can quickly conclude that the stresses and strains placed on the rear end multiply.

When we consider some of the Western classes, the stress and strain placed on the rear end change in form, but are equally severe. The cutting horse, for example, works almost completely off the rear end. Its back legs serve as both propulsion and brakes as the horse slides to a stop, then shoots forward or sideways as the cow turns and tries to escape. The process of turning while weight is suspended over the rear often places terrific torque on the hocks and can lead to soundness problems such as arthritis in the hock joint.

The reining horse also places stress and strain on the hocks during its pattern. There will be sliding stops, with most of the animal's weight transferred to the rear leg apparatus, and there will be spins, with

one back foot pretty much anchored in place as the horse does 360-degree turns, often at speed.

Different Stresses

Back to English riding, we find that dressage horses also place added strain on the rear end as they perform intricate patterns. The same is true of the jumper. In that discipline, we generally think in terms of more stress being placed on the front end as the horse lands after taking a jump. However, in order for the horse to land it has to take off, and it is the rear end that provides propulsion for a soaring jump.

While we generally don't think that much stress is placed on the rear end of trail horses, being ridden either in English or Western tack, there are times when the demands are high. An example would be climbing a steep hill or mountain where a strong rear end is required for propulsion upward as well as forward. When descending a steep slope, a strong rear end and sound legs also are needed, this time to provide braking capability that allows a horse to travel downward slowly and safely.

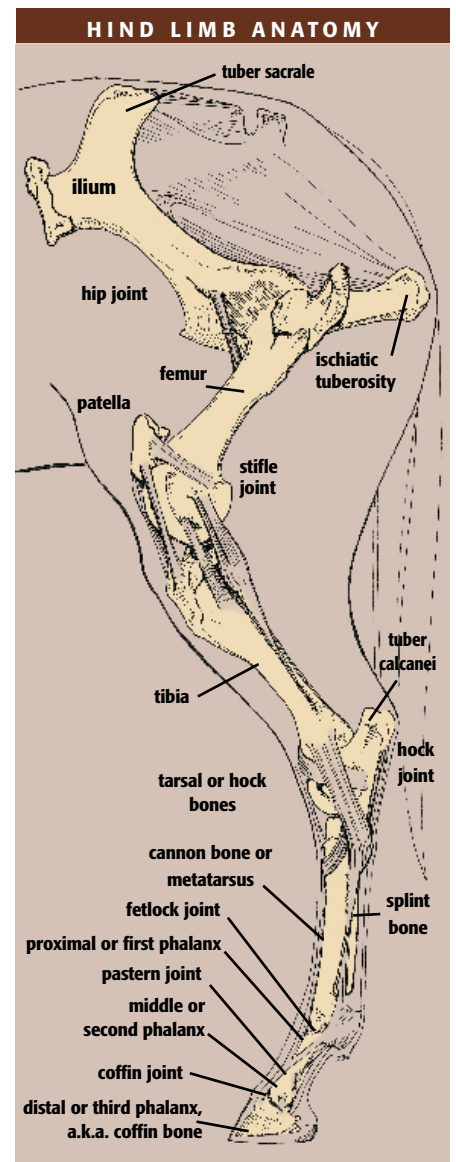
What this all means is that, regardless of discipline, we want a horse to have excellent rear leg conformation so that it can tolerate the demands placed on it by respective disciplines and still remain sound.

(A discussion of the roles played by muscles, tendons, and ligaments to enable rear leg propulsion as well as braking action will appear in future articles.)

What to Look For

When examining the horse's back legs, we want to look at the limbs from the rear and the side. We'll start with a view from the rear. We want to see a horse that is evenly balanced. This means that the distance between its thigh area, as well as between the hocks, should be about the same as the distance between the rear feet as they rest on the ground. The back legs should be straight from this viewpoint. If a vertical line were drawn on a photo taken from behind, the line would go as straight as a plumb line from the center of the buttocks, downward through the center of the entire rear leg, all the way distally through pastern and hoof to ground level.

Now let's take a step to the side. From this viewpoint, we must keep in mind proper angle. The angle of the stifle and hock should be neither too straight nor too angular, but should present a well-balanced picture with muscles running smoothly down the leg to the hock.



If we call into play again our imaginary plumb line, we should be able to start it at the rear of the buttocks and drop a straight line downward to the hock and along the cannon bone until it reaches the ground three to four inches behind the heel.

What we are describing is ideal rear leg conformation. Unfortunately, few horses have perfect leg conformation, front or rear. Some deviations are minor and others are major. The type of deviation and the severity goes a long way in determining whether the horse will remain sound.

Here are the four most common deviations in rear leg conformation that can cause problems, particularly if they are severe:

Cow-hocked—With this condition, when looking at the horse from the rear, the distance between the feet on the ground will be greater than the distance between the hocks. A mildly cow-hocked horse can perform in most disciplines without severe



stress. However, if the deviation is exaggerated, undue pressure will be placed on the hock joint (especially the medial or inside aspect) with each stop or strong propulsion forward, and there is the added danger of

the horse interfering.

Bow-hocked—This is the reverse of the condition described above. Here, when looking at the horse from the rear, the distance between the back feet will be less than the distance between the hocks. While neither condition is desirable, base-narrow often presents more of a risk to the horse than base-wide. With hocks that are far apart, extreme strain is placed on the joint with each stride and lameness can quickly result in a demanding discipline. There is still another downside for the base-narrow

horse. Rarely is a horse with this conformational fault a good athlete. The reason is quite basic—the horse is unable to make proper use of its muscles in either propelling itself forward or braking to a stop.

Sickle-hocked—When we look at a well-conformed horse from the side, we are able to drop our imaginary plumb line and it will travel vertically along the rear of the cannon bone, hitting the ground behind the rear hoof. With the sickle-hocked horse, there will be space between our plumb line and the rear cannon bone, almost from the upper point of the hock downward. A severe deviation with this condition places a great deal of stress on the rear of the hock and can quickly bring unsoundness. It should be kept in mind that in some breeds and disciplines—in particular draft horses for pulling—this conformation is preferred.

Straight behind—This the opposite of sickle-hocked. In this case there is very little angulation of the femur and the tibia. This condition is capable of placing heavy stress on the stifle joint and the hock. When these horses are used for roping, cutting, or reining, they are prone to injury because the rear legs are incapable of properly using muscles that are designed to help absorb concussion.

Back to the Top

Early on we mentioned that the shape or angulation of the horse's pelvis determines croup conformation. The conformation can range from straight to severely sloped, with a variety of degrees in between. The slope of the croup helps to determine the discipline for which the particular horse is designed. As a general rule, horses with a sloped croup will perform well in cutting, reining, and roping, and horses with level croups—such as the Saddlebred—are more apt to show up in gaited and fine harness classes or sometimes as racehorses.

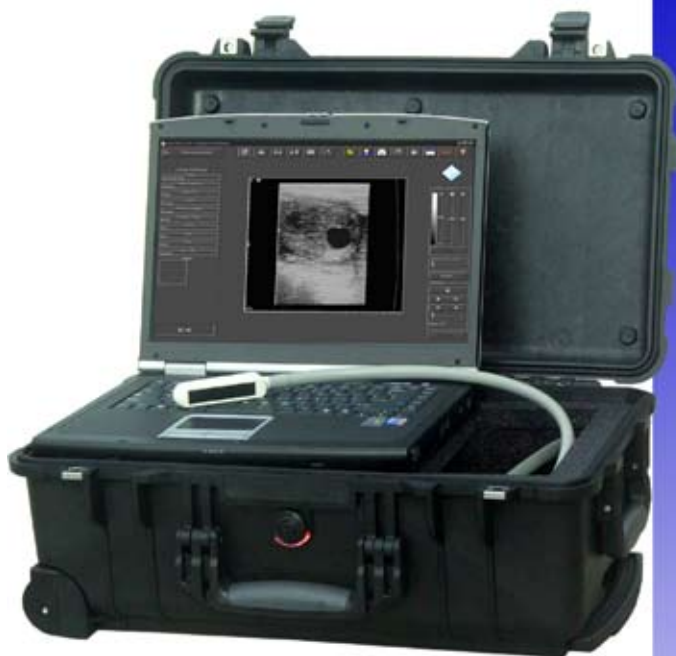Take-Home Message

No matter what the breed of horse and no matter what the discipline he performs, good rear leg conformation is highly important if a horse is to be a successful performer and remain sound. 🐾

ABOUT THE AUTHOR

Les Sellnow is a free-lance writer based near Riverton, Wyo. He specializes in articles on equine research, and he operates a ranch where he raises horses and livestock. He has authored several fiction and non-fiction books, including Understanding Equine Lameness, Understanding The Young Horse, and The Journey of the Western Horse, published by Eclipse Press and available at www.ExclusivelyEquine.com or by calling 800/582-5604.

*Experience the Evolution....
Computer Ultrasound for the Digital Office*



Digital Image Capture
Easy to Use Interface
High Quality Images
Easy to Add Programs

19900 Mona Road, #105 • Tequesta, Florida 33469
(800) 722-6838 • (561) 746-9527 • info@classicmed.com

www.classicmedical.com

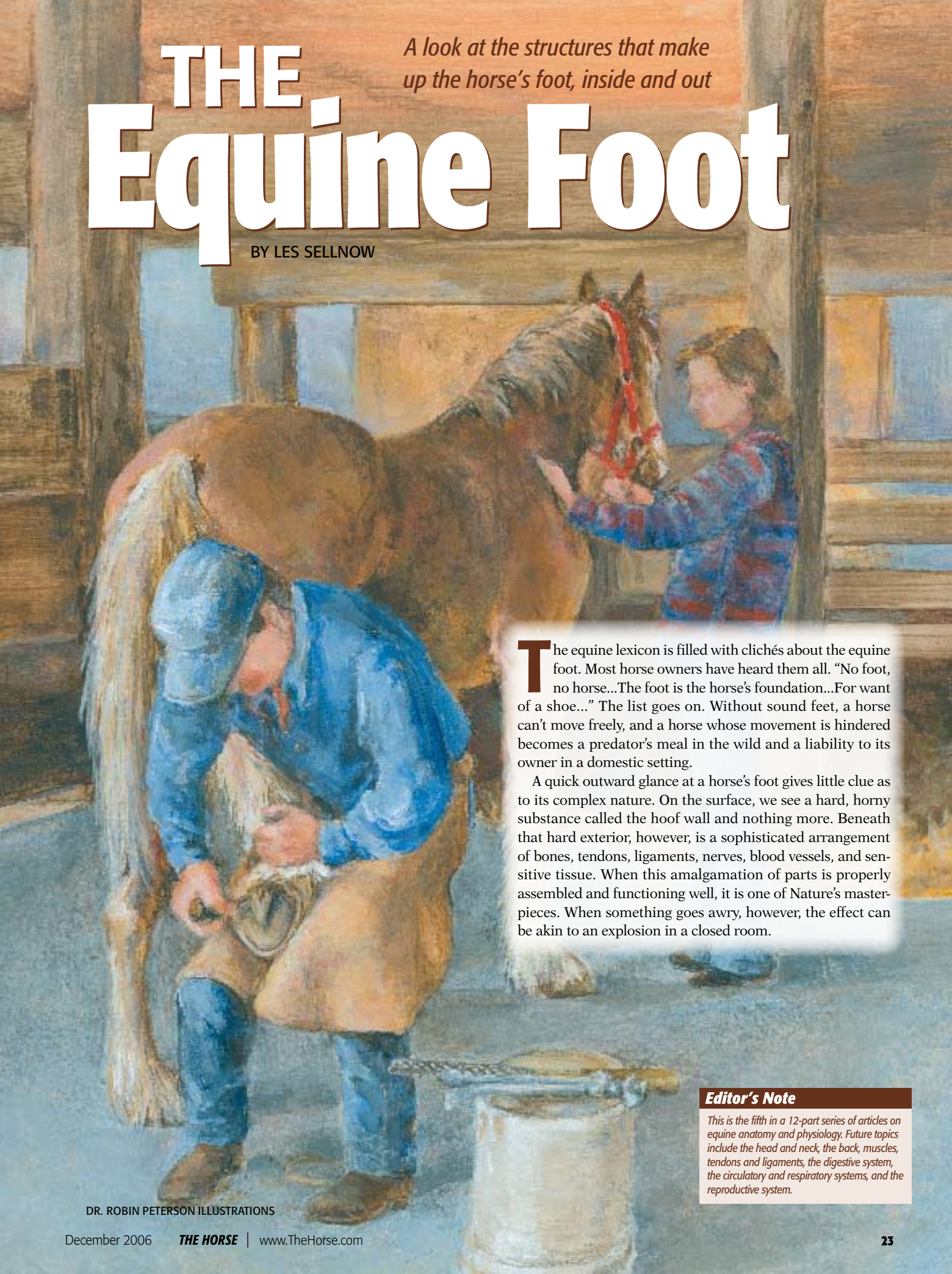

Notebook Ultrasound

THE Equine Foot

BY LES SELNOW

A look at the structures that make up the horse's foot, inside and out



The equine lexicon is filled with clichés about the equine foot. Most horse owners have heard them all. “No foot, no horse...The foot is the horse’s foundation...For want of a shoe...” The list goes on. Without sound feet, a horse can’t move freely, and a horse whose movement is hindered becomes a predator’s meal in the wild and a liability to its owner in a domestic setting.

A quick outward glance at a horse’s foot gives little clue as to its complex nature. On the surface, we see a hard, horny substance called the hoof wall and nothing more. Beneath that hard exterior, however, is a sophisticated arrangement of bones, tendons, ligaments, nerves, blood vessels, and sensitive tissue. When this amalgamation of parts is properly assembled and functioning well, it is one of Nature’s masterpieces. When something goes awry, however, the effect can be akin to an explosion in a closed room.

Editor’s Note

This is the fifth in a 12-part series of articles on equine anatomy and physiology. Future topics include the head and neck, the back, muscles, tendons and ligaments, the digestive system, the circulatory and respiratory systems, and the reproductive system.

DR. ROBIN PETERSON ILLUSTRATIONS

That hard, horny hoof wall is not malleable. When an injury or systemic insult causes blood vessels to expand or tissues to swell, there is no room to accommodate enlargement of any kind and something must give.

We will examine the anatomy of the foot in this article. Once again, we use a variety of sources, but two deserve additional mention. They are Doug Butler, PhD, Certified Journeyman Farrier, Fellow of the Worshipful Company of Farriers, of Colorado, a lecturer, author, and consultant; and David Hood, DVM, PhD, a professor at Texas A&M University who has been involved in that institution's Hoof Project. Information from these researchers comes from past interviews and papers they have authored. Other information comes from a variety of papers and textbooks.

It should be noted that hoof and foot are not synonymous. The hoof or hoof wall, generally speaking, is the three-layered outer surface of the foot. The foot, on the other hand, includes the hoof and all the bones, blood vessels, ligaments, tendons, and nerves therein.

The Outer Hoof

We begin with that rather innocuous-appearing exterior hoof wall. It plays a complicated role to house and protect the sensitive inner foot, support weight, resist wear, conduct moisture, and absorb shock.

In order to accomplish these tasks, the hoof wall and the foot must be healthy. It is at this point that the owner or caretaker plays a role. Because we have the horse in an environment of our choosing, the natural selection process does not come into play. In the wild, a horse with poor feet didn't survive and its genes were not passed on. Not so today. Some horses with horrid feet

are included in breeding programs because of their talent and capabilities in the show ring or on the racetrack. As a result, special care sometimes becomes the norm in order to keep these hooves and feet functional.

The hoof wall is composed of three distinct layers. The outer layer is the periople (like the human cuticle) and stratum tectorium. The periople extends about three-fourths of an inch below the coronet, except at the heels, where it caps the bulbs of the heels. The coronet encircles the upper area of the hoof and is the point of demarcation between the skin and the beginning of the hoof wall. The stratum tectorium, much like the human fingernail, extends down to the bottom of the foot. It is a thin layer of horny scales—hardened cells—that provides the hard, glossy-appearing surface below the periople. It is composed of keratinized epithelial cells that are solidly cemented together with keratin. One of its tasks is to protect the hoof wall from drying out. The hoof wall should be

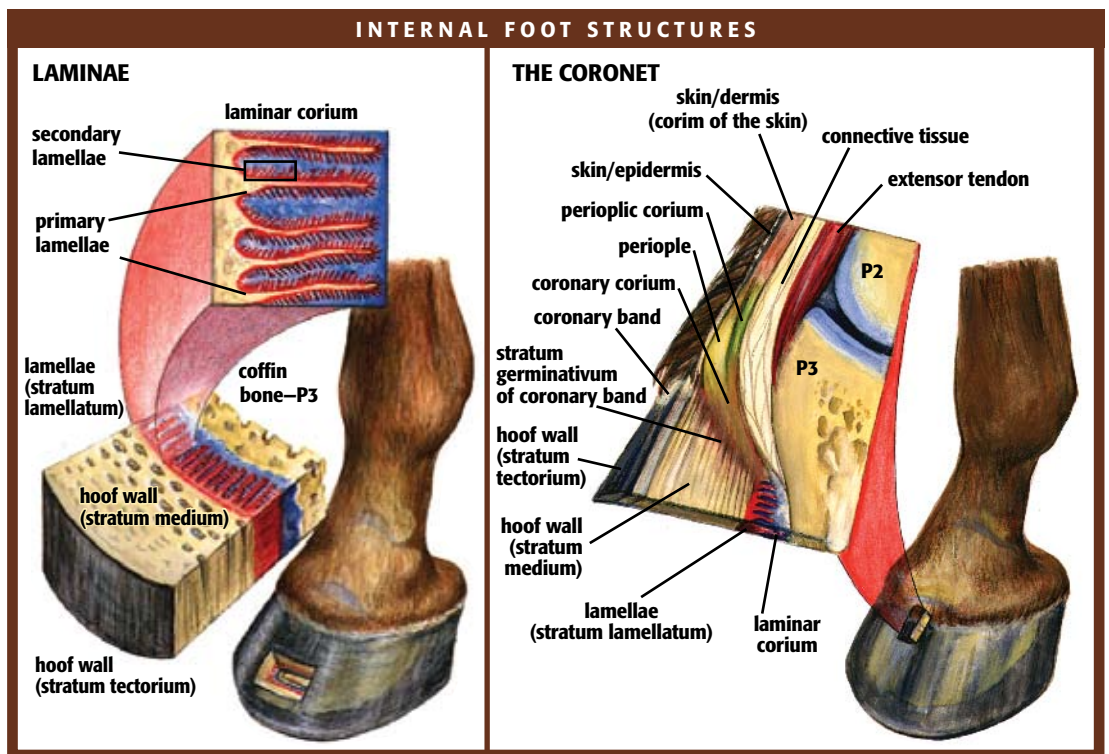
combined laminae bear much of the weight of the horse.

The junction between the laminae of the wall and the tubules of the sole is known as the white line.

Let's pause for a review of terms. The external surface at the front of the foot is its dorsal surface, and the surface facing the ground is the solar surface. On the front leg, the caudal (rear) aspect of the foot is its palmar surface. In the rear leg this is referred to as the plantar surface. Medial (inside) is the term for the portion of the foot nearest the foot on the opposite side. Lateral (outside) is the term for the portion of the foot farthest away.

On all surfaces of the hoof wall are small, thin, generally parallel lines that reach from the coronet to the solar surface. These lines are the tubules of the wall. The tubules are constructed in such a way that they resist compression of the hoof wall when the horse's foot bears weight.

Beneath the surface of the coronet is the



approximately 25% water:

The middle layer of the hoof wall comprises the bulk of the wall and is the densest portion. The inner layer is the laminar layer. It is concave from side to side and bears a multitude of primary and secondary leaf-like laminae, which attach the coffin bone to the inside of the hoof wall, similar to Velcro. There are some 600 primary laminae, each of which bears 100 or more secondary laminae on its surface. These

coronary band. It is the primary growth and nutritional source for the hoof wall. Within this structure lies a massive supply of blood vessels that feed the hoof. These blood vessels, combined with nerves, form a sensitive layer that is attached to the inside of the hoof wall and the third phalanx (coffin bone).

Injury to the coronary band can have a serious negative effect on hoof growth and development. If the injury to the coronary

band is serious, it can result in permanent disfigurement of the hoof and, in some cases, disrupt proper hoof growth to the point where the horse is no longer usable.

Time to learn another term—corium. Understanding its role helps to understand how the foot is nourished. The corium is a modified vascular (supplied with blood vessels) tissue that is divided into five parts. First is the perioplic corium, which is a narrow band lying in the perioplic groove above the coronary border of the wall. Its job is to distribute nourishment around the top of the hoof wall. Second is the coronary corium, which, with the perioplic corium, helps to form the coronary band. It furnishes the bulk of nutrition to the hoof wall and is responsible for growth of the wall. Third is the laminar corium that is attached to the coffin bone and nourishes the dermal laminae, the epidermal laminae of the wall, and the inter-laminar horn of the white line. Fourth is the sole corium, which is composed of fine hair-like papillae over the entire inner surface of the sole. These papillae furnish nourishment and growth to the sole. Fifth is the frog corium, which is similar in structure to the sole corium and furnishes nourishment and growth to the frog.

Back to the parts of the foot that are readily visible. On the solar surface is the sole. The structure of the sole is similar to that of the wall, with tubules running vertically as formed by the papillae of the sole corium. These tubules curl near the ground surface, which accounts for the self-limiting growth of the sole and causes shedding. The sole is not designed to constantly bear weight from the ground surface, but it is designed to bear internal weight.

An integral part of the foot is the frog, a wedge-shaped mass that occupies angles bounded by the bars and the sole. The frog is divided into the apex, which is the forward-most point; the base, which is the rear portion; and the frog stay, which is the central ridge. The frog is about 50% water and is quite soft.

The frog serves as a shock absorber in two ways. First, it helps absorb concussive force from the ground and, second, it acts as a stop that redirects concussive force coming down from the bony column through the lateral cartilages and the hoof.

The heels of the hoof form the most caudal part of the bearing surface of the hoof wall. There the wall makes an acute change in direction, turning back toward the toe. The portions that turn toward the toe are the bars of the foot.

The Skeletal System

The bones of the foot provide framework and facilitate locomotion. Nature did an excellent job in designing the bones. They had to be light enough to facilitate easy movement, yet strong enough to sustain the rigors of weight-bearing and concussion. When all goes well, they fulfill their roles admirably. However, when something goes awry with the bones, the result can be devastating lameness that is difficult to treat because of their location inside the horny hoof wall.

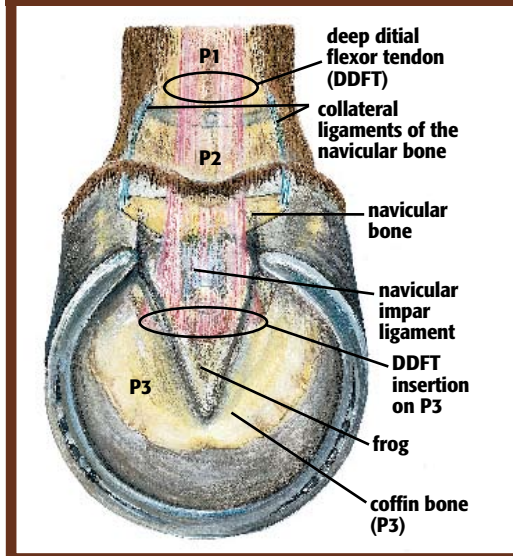
The three bones of the foot are the distal end of the short pastern bone, also known as second phalanx (P2) or middle phalanx (which extends distally from its connection with the pastern bone or first phalanx (P1); the coffin bone, also known as the third phalanx (P3) or distal phalanx (which extends distally from the short pastern bone); and the navicular bone, also known as the distal sesamoid bone, located behind and distal to the short pastern bone and behind and proximal to the coffin bone. The bones of the foot and leg are connected by joints and ligaments, so an injury to one can have a negative effect on the others.

Soft Tissues

There are two key tendons within the foot. The extensor tendon attaches to the front of the coffin bone and the deep digital flexor tendon attaches to the bottom of the coffin bone.

The navicular bursa is positioned between the deep digital flexor tendon and the flexor surface of the navicular bone and helps reduce concussion on the bone. Another inner foot structure that helps absorb concussion is the digital cushion located between the distal coffin bone and the sole. The digital cushion is a wedge-shaped structure with a fibro-fatty composition. It is very elastic and has very few blood vessels or nerves. When the digital cushion is compressed by the pastern bones and frog with weight bearing, it absorbs shock, cushions the bones, and is divided by the frog's exterior spine so that it is forced outward and obliquely upward against the lateral cartilages. The lateral cartilages are part fibrous tissue and part hyaline cartilage. They slope upward and backward from the wings of the coffin bone and reach above the margin of the coronary band.

BONES AND STRUCTURES OF THE FOOT



The coronary cushion is the elastic portion of the coronary band. It is a fibro-fatty cushion that is thickest in the center and thinnest at the quarters where it attaches to the lateral cartilage. It then widens out and thickens to form the base of the bulbs of the heel, where it blends in with the digital cushion. The coronary cushion helps in the reduction and transfer of compression between the hoof wall and the coffin bone as well as other internal foot parts.

The inner foot is serviced by a blood supply that is pumped by the heart through the arteries to the foot and is assisted in its return to the heart by a pumping mechanism within the foot facilitated by compression involving a complex network of veins whenever the horse bears weight on the foot. The lymphatic system of the limbs also requires this pumping action to move fluids. This is one reason that a horse standing still for a long time will “stock up” because fluids in the legs are not being pumped back up the limbs by cycles of foot loading and unloading.

Take-Home Message

Because the foot plays such a key role in the horse's ability to survive and function, we will end this dissertation on the anatomy of the foot with the oldest of clichés: “No foot, no horse.” 🐾

ABOUT THE AUTHOR

Les Sellnow is a free-lance writer based near Riverton, Wyo. He specializes in articles on equine research, and he operates a ranch where he raises horses and livestock. He has authored several fiction and non-fiction books, including Understanding Equine Lameness, Understanding The Young Horse, and The Journey of the Western Horse, published by Eclipse Press and available at www.ExclusivelyEquine.com or by calling 800/582-5604.

Anatomy—The Head and Neck

BY LES SELLNOW

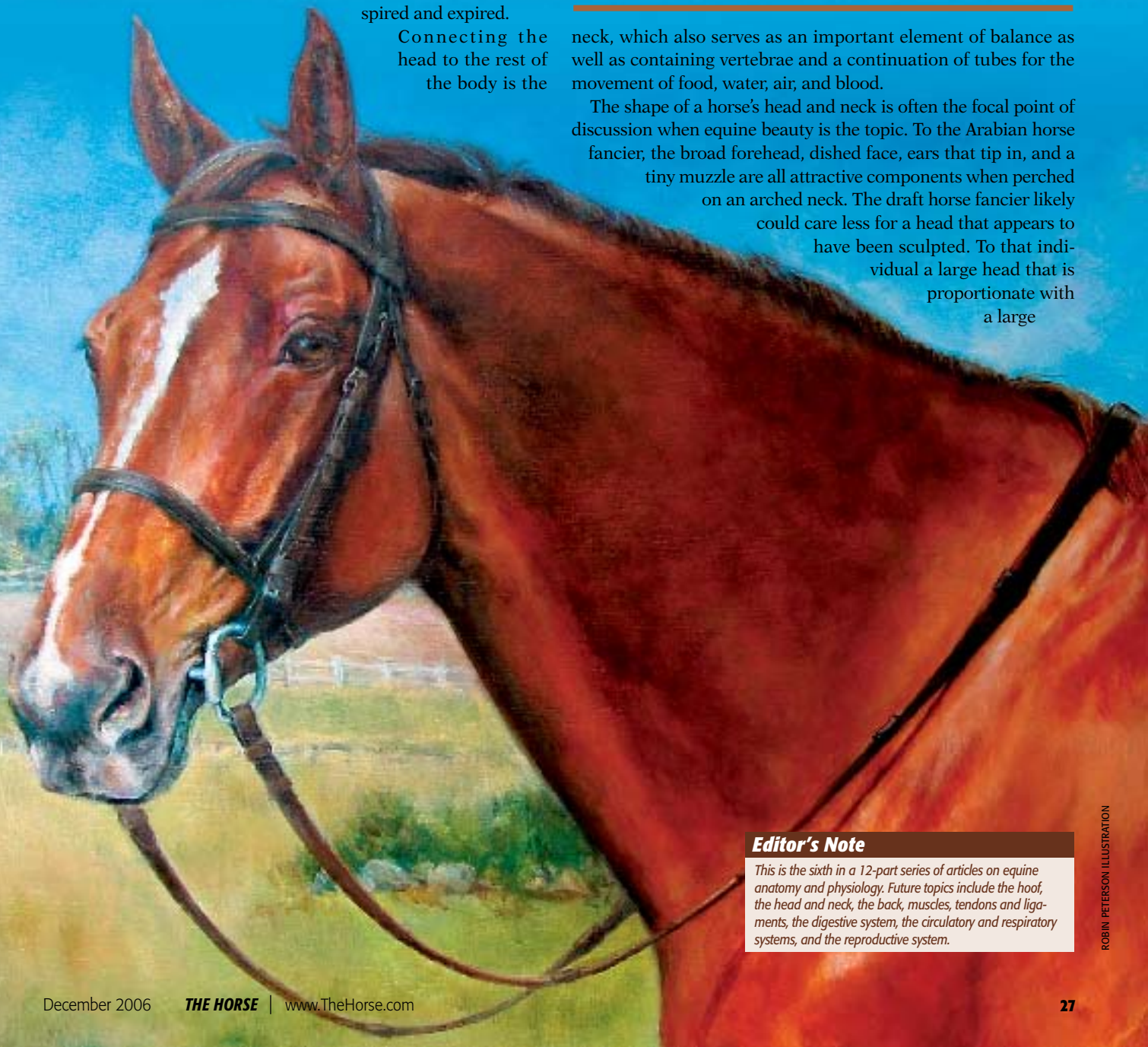The equine head can be compared to a computer. Housed within the skull are the major “components—the brain and the sense organs. In addition to functioning like a computer, the equine head contains teeth for cropping grass and chewing food, and all of the necessary components for moving the food to the digestive system, as well as housing the respiratory apparatus that allows for air to be inspired and expired.

Connecting the head to the rest of the body is the

No matter the conformation of your chosen breed, the heads and necks of horses serve many purposes

neck, which also serves as an important element of balance as well as containing vertebrae and a continuation of tubes for the movement of food, water, air, and blood.

The shape of a horse’s head and neck is often the focal point of discussion when equine beauty is the topic. To the Arabian horse fancier, the broad forehead, dished face, ears that tip in, and a tiny muzzle are all attractive components when perched on an arched neck. The draft horse fancier likely could care less for a head that appears to have been sculpted. To that individual a large head that is proportionate with a large



Editor's Note

This is the sixth in a 12-part series of articles on equine anatomy and physiology. Future topics include the hoof, the head and neck, the back, muscles, tendons and ligaments, the digestive system, the circulatory and respiratory systems, and the reproductive system.

body and a neck that is muscular and strong are the components being sought.

An anatomically correct horse will have a head that is proportionate to its body size, and the shape will be characteristic of the breed.

There are a couple of other requirements when looking at the ideal equine head. The forehead should be broad and well defined to provide space for wide-set eyes. The lower jaw should also be well defined and with good width between the branches so that there is ample space for the larynx. In addition, the nostrils should be wide and capable of flaring into even larger openings so the horse can increase air intake during exercise. (While that point is widely held by many horse owners, there are those in the scientific community who say there is little or no research data to support the contention that flaring nostrils permit additional intake of air.)

As we explore the anatomy of the equine head and neck, it must be pointed out that the information in this article comes from a wide variety of sources, including textbooks and papers on equine anatomy. However, special attribution must once again be given to *The Coloring Atlas Of The Horse*, authored by former Colorado State University faculty members Thomas O. McCracken, MS, and Robert A. Kainer, DVM, MS.

Bone Head, With Lots of Air

It might come as a surprise to some horse owners to realize the equine skull is comprised of 34 bones, most of them flat.

During the birthing process, these bones yield and overlap, allowing the skull to be somewhat compressed and thus allowing for easier parturition. The bones have fibrous joints, which are basically

immovable joints where the bones are bound by fibrous tissue that ossifies as the horse matures.

The equine brain is located within a cranial cavity. The cranial cavity is partially divided by a down-growth of the skull roof, with the rostral compartment housing the cerebral hemispheres of the forebrain and the caudal compartment housing the cerebellum of the rear brain. The brain is continuous with the spinal cord. The brain lies in the upper forehead of the horse and, of course, is the key component in this unique “computer.”

leads directly into the nasopharynx. The pharynx is a passageway, comprised of muscle and membranous tissue, that is located between the mouth-nostrils area and the larynx and esophagus. The portion of the pharynx above the level of the soft palate is the nasopharynx.

The larynx is the upper end of the trachea or windpipe. It is a tubular structure comprised of muscle and cartilage that contains the vocal cords and connects the nasopharynx with the trachea. The trachea is a cartilaginous and membranous tube descending from the larynx and branching into the right and left bronchi.

The roof of the mouth is formed from the hard palate in front and the soft palate close behind and continuous with it.

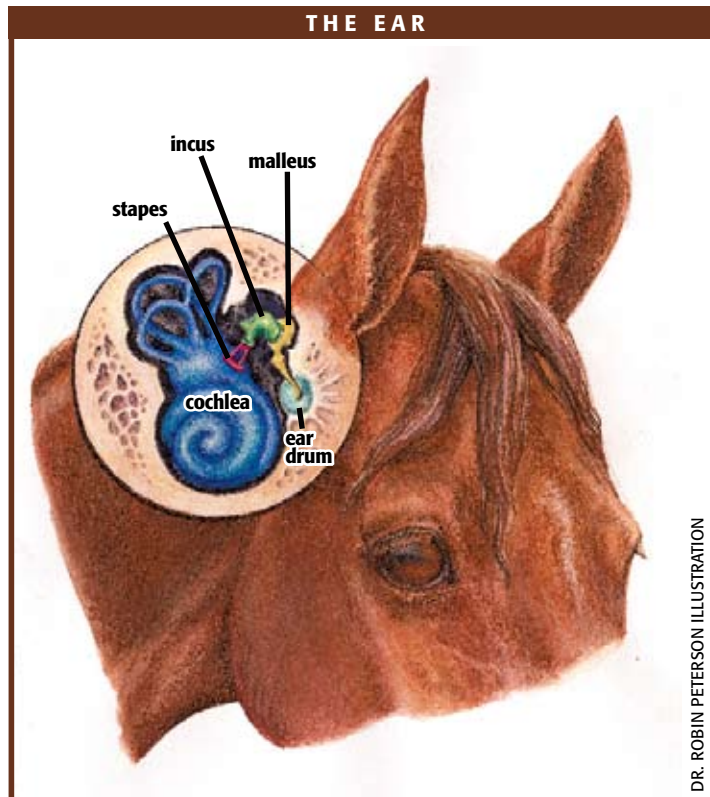
In technical terms, with an assist from the above-mentioned authors, here is how the apparatus functions:

When the horse is breathing, the free edge of the soft palate is usually under the epiglottis and the laryngeal entrance is open. During swallowing, muscles raise the tongue, pressing food or water against the hard palate. The root of the tongue is pulled rearward, the laryngeal entrance is narrowed, and the soft palate is elevated to the caudal wall of the pharynx. Increased pressure in the pharynx forces feed or water into the esophagus where involuntary contractions cause

it to journey on to the stomach.

What this all means in simple terms is that during the breathing process, the pharynx and soft palate form a smooth, uninterrupted passageway for the flow of air into the trachea. When the horse swallows, the pharynx and soft palate move so that food is directed into the esophagus rather than the trachea. There can be a variety of afflictions capable of altering the soft palate, causing caudal displacement and preventing its return to the normal breathing position.

Lending a major assist in preventing food from being inspired into the lungs is the epiglottis, a lid-like structure overhanging the entrance to the larynx. Its job is to close the laryngeal opening when the horse swallows, thus making certain that



DR. ROBIN PETERSON ILLUSTRATION

The respiratory tract starts with the nostrils, which are the openings into the nasal cavity. The perpendicular partition separating the nasal cavity into left and right halves is known as the median nasal septum. It is composed of bony, cartilaginous, and membranous parts.

Structures within the nasal cavity include the turbinate bones, also known as nasal conchae. They contain mucous-secreting epithelium that functions as something of an air conditioning process as it warms, moisturizes, and filters inspired air. The nasal conchae and the median nasal septum divide the nasal cavity into passageways; each passageway is called a meatus.

The largest of these passageways is known as the ventral nasal meatus and

food and water head down the esophagus and into the stomach instead of winding up in the trachea and the lungs.

The horse's tongue lies on the floor of the mouth and is composed of a mass of muscle anchored by the hyoid bone and the bodies of the left and right mandibles—lower jaw.

Something To Chew On

One of the skull's most important components involves the teeth. They are used for cropping grass and grinding food as part of the masticating process. When a foal is born, it is generally toothless, but very soon it will have a full set of baby teeth (24). They are divided into six upper and six

lower incisors and six upper and six lower molars, and they are replaced with adult teeth around age three.

The adult male horse has six upper and six lower incisors; six upper and six lower pre-molars (the most forward set of cheek teeth); six upper and six lower molars (the cheek teeth at the rear of the mouth); two upper and two lower canine teeth; and two wolf teeth located adjacent to the premolars in the horse's upper jaw.

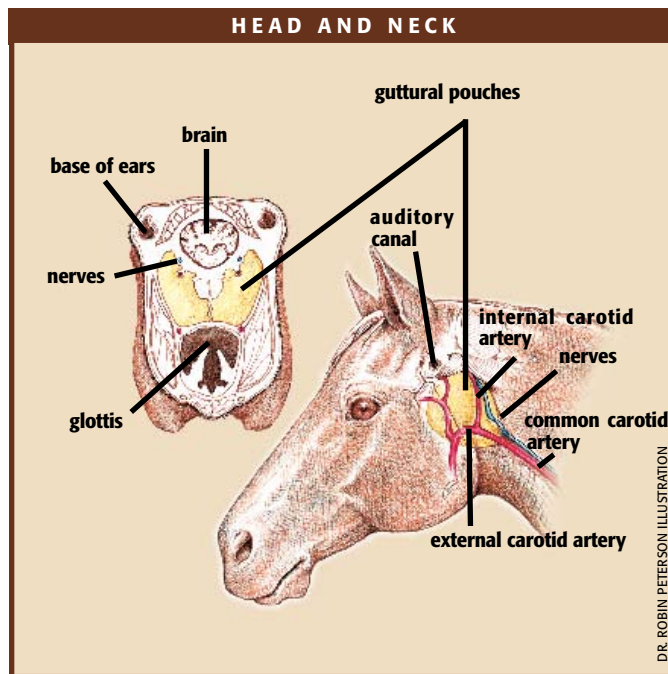
The incisors are used for cropping grass and the molars for grinding it in preparation for the digestive process. Aiding the cause are salivary glands that, in the adult horse, can produce as much as 10 gallons of saliva per day.

Adult females normally have the same complement of teeth as the males, minus the canine teeth.

The tooth of the horse is described as being hypsodont. Simply put, this means the teeth are constantly erupting as the grinding action of eating wears away the crown surface. One can compare it to chalk being used on a blackboard. After a time, the chalk becomes so short as to be worthless. It is basically the same with the horse's teeth.

Perhaps one of the most improved areas of equine health care involves dental procedures. Research has shown when teeth are properly cared for, it allows the horse to masticate its food better and, as a result, make better use of the nutrients being ingested.

In the past, many horse owners paid little attention to their horses' teeth,



DR. ROBIN PETERSON ILLUSTRATION

believing that it was best left in the hands of nature. That is no longer the case in much of the equine world today, and modern-day horses are healthier because of it.

The Better to See and Hear You...

There are some aspects of equine anatomy that have similarities to human anatomy; the eye is not one of them. The most basic difference stems from the fact that humans are predators and horses are prey animals. Thus, the eyes of humans are close together and can focus quickly on objects both near and far. Looking at objects to right or left involves turning the head in that direction. Human eyes are more comparable to the eyes of cats and dogs than horses.

As a prey animal, the horse has developed both monocular and binocular vision. This means that the horse can see an image with both eyes—binocular—or with one eye only—monocular. Humans have binocular vision only. With monocular vision, the brain often is receiving different messages from each of its eyes.

Important to the good health of equine eyes are the lacrimal glands located just above the eye. Tears secreted by the lacrimal glands wash over the eye and make their way downward, ultimately exiting through the

nasal opening. from all directions because horses have 16 auricular muscles controlling their pinna. After being trapped by the pinna, the collected sound waves are funneled through the external ear canal (commonly referred to as the auditory canal) to the middle ear, where they cause the eardrum, a thin membrane, to vibrate.

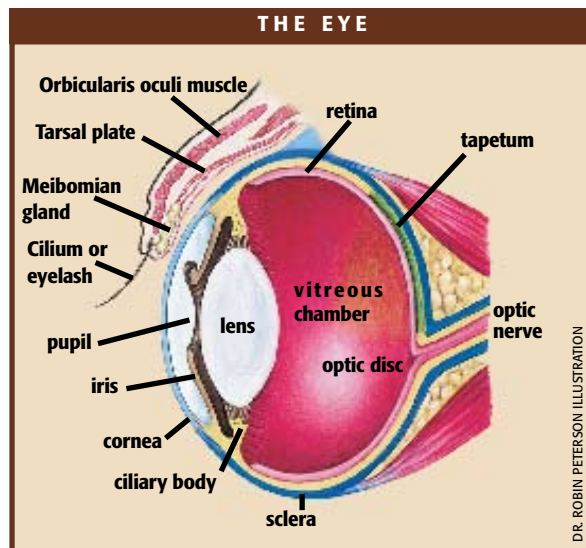
These vibrations are sent through the ossicles, a series of three tiny bones called the malleus, incus, and stapes. Finally, they reach the inner ear, where they cause vibrations in a snail-shaped structure called the cochlea.

Running up and down the cochlea are extremely sensitive hair cells that act as transducers. When these hair cells bend, they generate electrical signals that stimulate the auditory nerve. This nerve passes

nasal opening.

A horse's hearing is more acute than that of a human as its uniquely shaped ears funnel sounds to the brain. In a September 2005 article in *The Horse* (www.TheHorse.com/emag.aspx?id=6016), the writer noted that horses' ears are finely tuned instruments designed to convert sound waves in the environment into action potentials in the auditory nerve. This nerve, which is located at the base of the skull, sends information to the brain to be translated and interpreted.

The horse uses his pinna (the large, cup-like part of the ear that you can see) to collect sound waves from the environment. Made of cartilage, the pinna can rotate to capture sound waves



DR. ROBIN PETERSON ILLUSTRATION



attention to a component that is unique to the horse—guttural pouches. There is a guttural pouch on either side of the horse’s head, and each is divided into a larger inner and small outer compartment. The guttural pouch is a grapefruit-sized sac that is interposed in the eustachian tube that connects the middle ear with the nasal passage.

the impulses to the brain.

A Pouch for Trouble

Before leaving the skull, we must call at-

The normal guttural pouch can be described as an air-filled sac. However, while the image of a balloon comes to mind, the normal guttural pouch is not distended

with air, as is the case with an inflated balloon.

Why nature provided equids—and no other mammals—with guttural pouches is a mystery, with some scientists thinking the pouches might have something to do with balance. One thing is certain, when there is a fungal attack in the guttural pouch, it can be a serious health problem.

Along the Neck

As mentioned earlier, the shape of a horse’s neck can be involved in what one considers attractive or unattractive conformation, but that sometimes has little to do with function. A short, cresty neck is undesirable because it can inhibit proper function. If the thickness extends all the way into the throatlatch, it can cause problems. Both the trachea and the esophagus enter the neck at that point—as do a vital network of veins and arteries that convey the blood supply to and from the brain. When a horse with a thick throatlatch is asked to “set its head” or carry its head in a perpendicular frame, these vital passageways often are constricted.

A short, heavy neck also restricts the use of the neck and head as balancing mechanisms.

One of the methods utilized in determining optimum neck conformation is to measure the top and bottom of the neck. The top runs from the poll to the withers, and the bottom runs from the throatlatch to the neck-shoulder junction. The proper ratio in the minds of many is two to one, top to bottom.

There are seven cervical vertebrae in the horse’s neck, with the spinal cord exiting the brain and running through them. The vertebrae are connected via cartilaginous joints. These joints are slightly movable and are united by connective tissue. Problems that develop within, or to, the cervical vertebrae can mean serious problems.

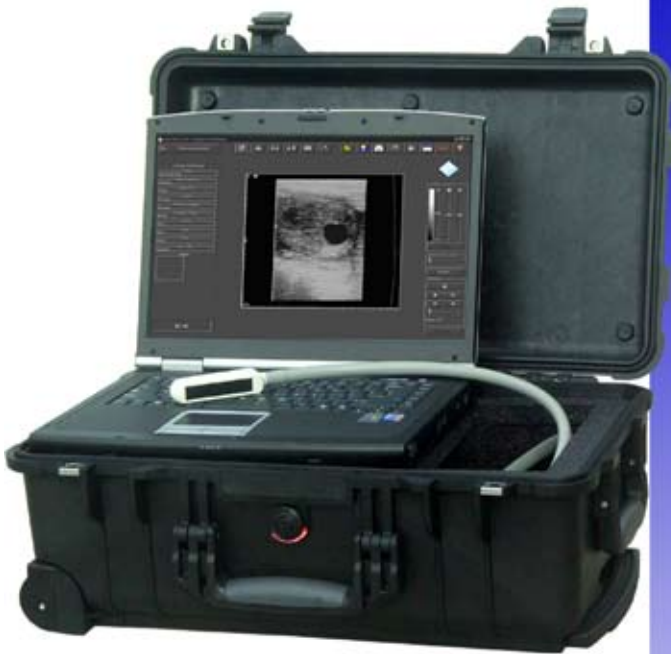There is a correlation between the length of the cervical vertebrae and the length of the neck—the longer the individual vertebrae, the longer the neck.

The vertebrae of the neck connect with the vertebral column of the back, which we will be discussing next month. ↙

ABOUT THE AUTHOR

Les Sellnow is a free-lance writer based near Riverton, Wyo. He specializes in articles on equine research, and he operates a ranch where he raises horses and livestock. He has authored several fiction and non-fiction books, including Understanding Equine Lameness, Understanding The Young Horse, and The Journey of the Western Horse, published by Eclipse Press and available at www.ExclusivelyEquine.com or by calling 800/582-5604.

*Experience the Evolution....
Computer Ultrasound for the Digital Office*



**Digital Image Capture
Easy to Use Interface
High Quality Images
Easy to Add Programs**

Classic Medical
Since 1985
Classic Digital IMAGING

Notebook Ultrasound

19900 Mona Road, #105 • Tequesta, Florida 33469
(800) 722-6838 • (561) 746-9527 • info@classicmed.com
www.classicmedical.com

The Equine Back

BY LES SELNOW

Horses have been carrying burdens on their backs since man discovered that he could cover more ground faster while riding a horse as opposed to striding along on his own two legs. Man also discovered that it was far less strenuous to pack a load on a horse's back rather than on his own.

As use of the horse increased, so did problems with the equine back. Some of them are the result of conformation. It takes a strong, well-conformed back to handle the rigors of trail riding, performing, and packing. Other problems have been man-made.

Even a horse with excellent conformation can wind up with back problems if ridden by a rider out of balance or if outfitted with inappropriate tack.

In this article, we'll take a look at the equine back—how it is structured, proper conformation, and some of the problems that can afflict it.

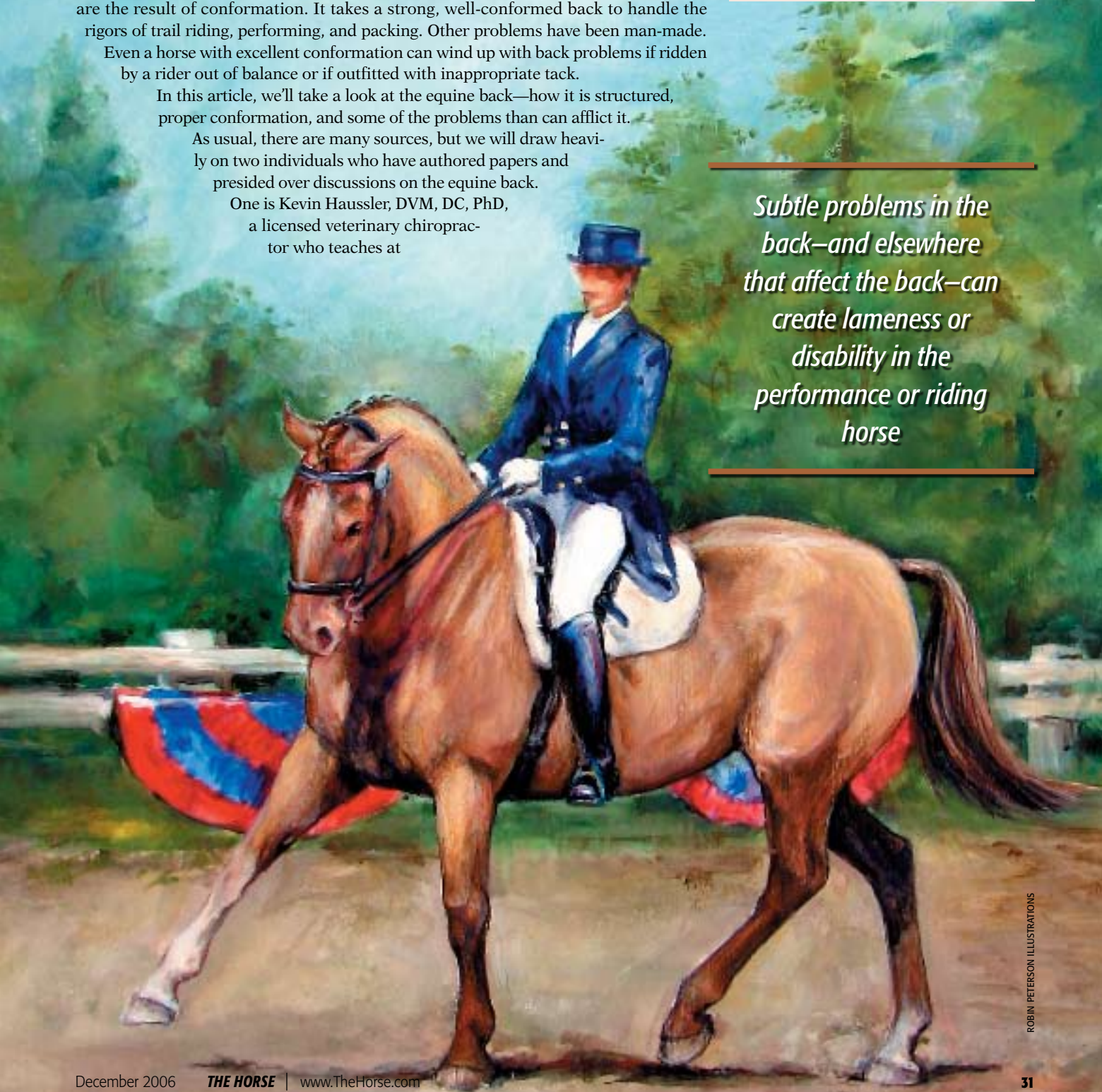As usual, there are many sources, but we will draw heavily on two individuals who have authored papers and presided over discussions on the equine back.

One is Kevin Haussler, DVM, DC, PhD, a licensed veterinary chiropractor who teaches at

Editor's Note

This is the seventh in a 12-part series of articles on equine anatomy and physiology. Future topics include muscles, tendons and ligaments, the digestive system, the circulatory and respiratory systems, and the reproductive system. Previous articles can be found on www.TheHorse.com.

Subtle problems in the back—and elsewhere that affect the back—can create lameness or disability in the performance or riding horse





Cornell University's School of Veterinary Medicine. Information from Haussler stems from interviews and presentations at AAEP conventions.

The other source is Doyle Meadows, PhD, a professor in the Animal Science Department at the University of Tennessee. One of Doyle's papers on equine conformation was included in the *Horse Industry Handbook* published by the American Youth Horse Council. In addition, we will draw on information included in anatomy textbooks.

The key component in a horse's back is his spine. It begins at the head and travels along the neck, withers, back, loin, and croup, and it ends in the tail. How this spinal column is conformed can have a great deal to do with the horse staying sound, healthy, and free of back pain even when involved in arduous pursuits.

Anatomy of the Spine

Generally speaking, the horse has 54 vertebrae in this spinal or vertebral column (vertebra is singular, vertebrae is plural). We say "generally speaking" because the number of vertebrae in a horse's tail can vary. Haussler tells us that there can be as few as 51 total vertebrae and as many as 57. Using 54 as our average total for this discussion, we find that there are seven cervical or neck vertebrae; 18 dorsal or thoracic vertebrae; six lumbar or loin vertebrae; five sacral or croup vertebrae; and 18 coccygeal or tail vertebrae.

The vertebrae are identified by clinicians and researchers by number from head to tail. For example, the first cervical vertebra is identified as C1 and the last one is C7. The thoracic vertebrae are prefaced by T and a number: T1 is the first thoracic vertebra and is located at the point of the shoulder where the thoracic column begins. The thoracic vertebrae end where the last rib attaches to the vertebral column.

The thoracic vertebrae closer to the neck have prominent dorsal spinal processes for

a particular reason. The processes or projections provide the site for attachment of muscles that support the head, neck and front legs. In like manner, the vertebrae of the sacral area help support the hind legs and the vertebral ligaments form broad attachments to the bones and muscles of the pelvis.

The Vertebrae

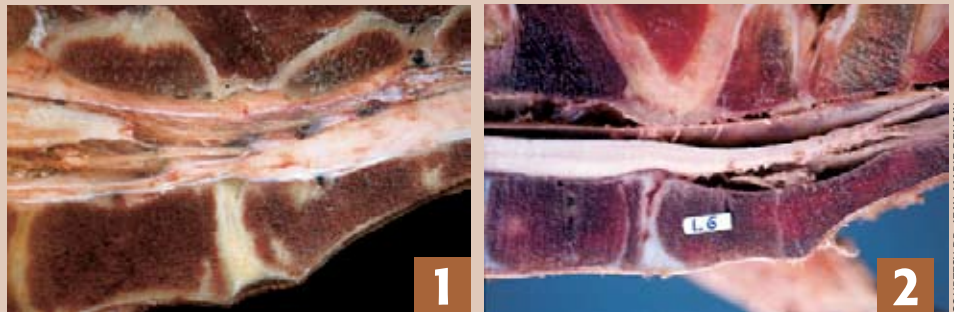
Now, with Haussler's help, along with textbook information, we'll take a look at the individual bones in the spine.

The typical vertebra consists of a vertebral body (the main bulk of the bone)

A significant characteristic of the spine is its rigidity. There is some movement from side to side and up and down along the back, but not a great deal.

In contrast, the vertebrae in the neck and in the tail are much more flexible, allowing the horse to raise and lower its head and move it from side to side. The flexibility of the tail provides the horse with a strong weapon against attacking insects. The amount and direction of flexibility is determined mostly by joint size and shape.

The joints that connect the vertebrae are known as cartilaginous joints. These are



Medial cross sections of the spine at the lumbosacral junction. Normal anatomy is shown in image 1; ankylosis and degeneration of L6 is shown in image 2.

COURTESY DR. JEAN-MARIE DENOIX

and several vertebral or spinal processes (smaller wings projecting off the vertebral body). The length of an individual vertebra can vary from one horse to another.

There is a strong correlation between vertebral length and the length of various component parts. For example, a horse with long vertebrae will tend to have a long neck, back, loin, croup, and tail. Again, more is not necessarily better. Yes, we want a horse to have a long neck, but no, we don't want it to be overly long and unwieldy. The same is true of the other areas of equine anatomy involved—back, loin, croup, and tail.

When discussing the properly conformed horse, we noted that the highest point of the back is at the withers, with a slight decline where the saddle rests, then an upward sweep at the croup. This does not mean that the spine itself is much higher or lower at any point along the back. Instead, the dorsal spinal process on the vertebrae's upper surfaces are involved. These bony, finlike projections are at their longest at the withers and at their shortest under the saddle, then project upward a bit more in the hip area. The spine itself runs in pretty much a straight line all along the back.

joints that are slightly movable or immovable, depending on the bones involved. Cartilaginous joints are united by fibrocartilage, hyaline cartilage, or both. The connective tissue between two vertebrae is comprised of both types of cartilage. Cartilage and soft tissue form discs between individual vertebrae to absorb the shock and concussion produced by movement.

Back Conformation

Now we turn to Meadows for assistance in describing proper equine back conformation. Once we have this picture in mind, it will be easier to understand form and function of the back.

When considering a properly conformed horse, the withers will be the highest point of the back. A prominent withers ensures that the saddle will stay in place without excessive cinching. The equine backbone, overall, is arched slightly upward, thus helping provide strength and durability. However, it also is a case where more is not better. If the back is arched too much, the horse is said to be roach backed, a condition that can be the source of soreness and a limitation of performance capability. On the other hand, if the back sags markedly, we say the horse is sway-backed or

suffering from lordosis. This, too, is a condition that will cause a saddle to fit poorly and can be the source of soreness and a wide variety of other back problems.

When viewed from the side, the topline—the distance between the withers and croup—should be less than the distance between front and rear legs along the belly, or underline. If the topline is longer, it is an indication that the horse's back is too long and that it will be weak and lacking in balance. There should be a slight dip behind the withers where the saddle rests and a gentle sweep upward over the loins and point of croup.

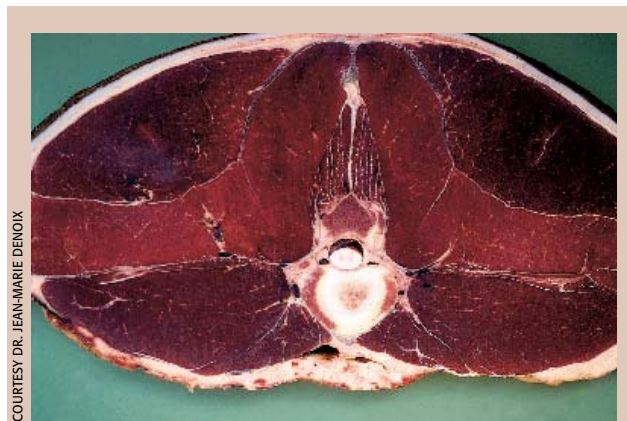A key part of back conformation is the loin—the area between the last rib and the croup. The loin should be well-muscled, strong, and relatively short so that it can convey power from the rear legs forward.

The croup is the area that extends from the loins to the tailhead. It should be long and gently sloping, with the amount of slope varying from breed to breed and horse to horse. A long croup enables a horse to have a long stride as well as providing a setting for proper dimension and solid muscling in the hindquarters.

Strength and Flexibility

Strong muscles are needed to support the back. They are divided into two categories—superficial and deep.

The large, superficial back muscles span large regions of the spine and ensure coordinated back movements. Smaller, deep back muscles connect one or two vertebrae and act to move or stabilize each individual vertebra.



A cross section of the back shows the spine and soft tissues (muscles, tendons, and ligaments) surrounding the spine.

Spinal ligaments connect the individual vertebrae and provide joint support. In addition, the horse's spinal column is held under tension by the horse's belly muscles.

The relative rigidity of the back provides the strength needed to support a rider's weight. However, there are disciplines where at least some movement at the vertebral joints in the thoracic and lumbar areas is required.

Perhaps the discipline that requires the greatest range of spinal movement and strength is dressage. Jumping high fences also requires movement in the form of rotation of the back and hind limbs.

One of the prime responsibilities of the vertebral column is to protect the spinal cord that runs through it and the complex nerve system that branches from the spinal cord at intervals all along the spine. As the nerve structure exits the spine, the nerves divide into various branches that fan out within the horse's body and go to the joints, muscles, internal organs, and skin.

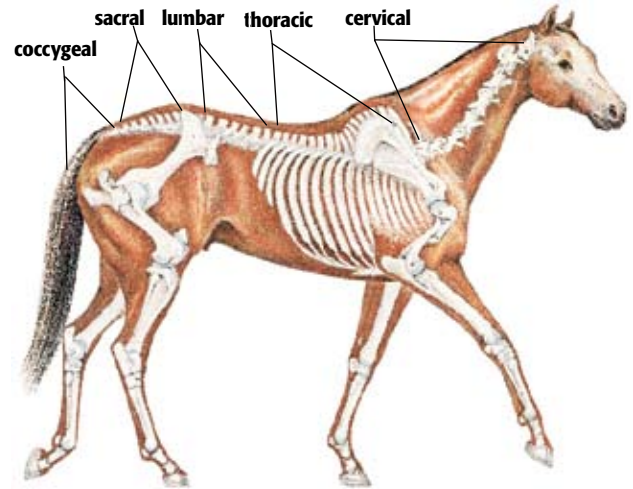
Nerve impulses travel from the brain and spinal cord and out of the spinal nerves to all parts of the body. Similarly, nerve impulses travel back to the brain via the peripheral nerves and spinal cord. The horse's overall nerve structure serves as the message-carrying system between

the brain and all areas of the body. Nerves also can sense pain and joint movement. Pain sensors are found in the bones, joints, muscles, ligaments, and blood vessels of the back.

When joints or muscles don't function correctly or nerves are irritated, the message system falters.

The diameter of the spinal cord is at its greatest in the cervical and lumbar regions.

These are the areas where nerve roots for the plexuses (a network of nerves) supplying the nerves of the limbs originate. These two areas are referred to as the cervical and lumbar en-



The horse's spinal column starts at the poll and goes to the end of the tail (see areas defined above).

largements.

When we consider that we are dealing with an area of equine anatomy with relatively small joints with little movement, it becomes apparent that there is potential for performance-limiting injuries if something happens to damage this relatively rigid structure.

Helping Injuries

In the past, when a back injury was suspected, about the only therapy utilized was rest. In more recent years, however, new weapons have been added to a veterinarians' arsenal, including chiropractic and acupuncture.

Back and neck injuries in the horse can involve a variety of causes. Often the injury stems from trauma, such as a fall or tipping over backward. Problems also can stem from poor conformation, poor saddle fit, over-exertion, and lack of fitness.

Haussler provides us with three classifications for spinal injuries:

- Soft tissue injuries involving muscles, tendons, and ligaments.
- Osseous injuries involving bones and joints; and
- Neurological injuries involving the nervous system.

When dealing with chiropractic, one term is heard with frequency: Subluxation. Technically, subluxation means a partial dislocation of a joint. However, in chiropractic terminology, it describes the loss of normal motion due to pain, muscle spasms, or joint stiffness. With subluxation, the joint surfaces are almost, but not



quite, in the correct position. The joint still functions, but not as well, and might be painful. There might also be an impingement of the spinal nerves that exit between

the pairs of vertebrae.

Sometimes a subluxation problem is solved naturally, such as a horse rolling, bending, or stretching. At other times, however, the problem persists and calls for treatment. In many cases, the treatment protocol involves both a veterinarian and a chiropractor working under the auspices of the attending veterinarian. (Today, more and more veterinarians are adding chiropractic credentials to their portfolio.) The reason for the dual approach is that many back problems are secondary to a primary

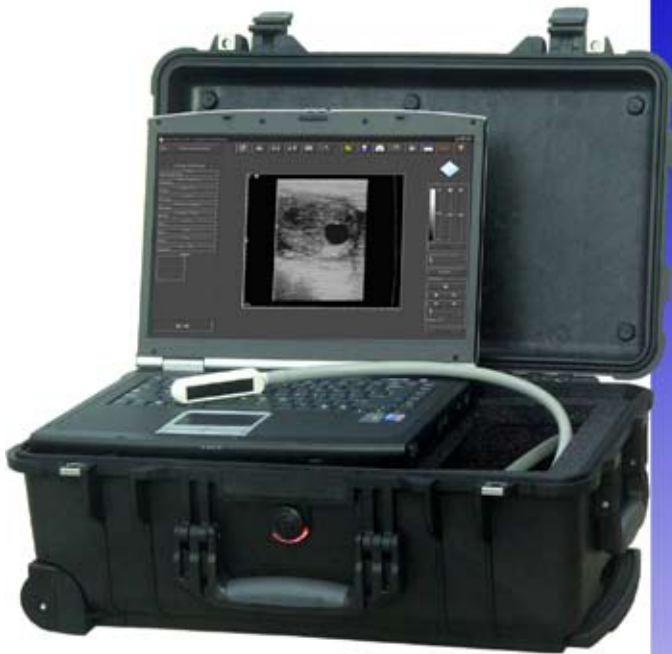problem. When that is the case, the back problem won't be alleviated, no matter what treatment is used, until the primary cause is removed.

The chiropractic adjustment consists of a short, sharp thrust with the hands to a specific area of the back. The approach is designed to release muscle spasms, alleviate pain, and return the joint to its normal range of motion.

Normally, there are few side effects after chiropractic treatment, but a horse might occasionally become stiff and sore after being treated, especially if there is a lot of inflammation or bony pathology, such as acute or active arthritis.

Other back problems, such as those involving the discs between each pair of vertebrae, often are much more complicated—as is the case with humans—and could require a different approach.

*Experience the Evolution....
Computer Ultrasound for the Digital Office*



Digital Image Capture
Easy to Use Interface
High Quality Images
Easy to Add Programs

19900 Mona Road, #105 • Tequesta, Florida 33469
(800) 722-6838 • (561) 746-9527 • info@classicmed.com

www.classicmedical.com



Notebook Ultrasound

The chiropractic adjustment consists of a short, sharp thrust with the hands to a specific area of the back.

Take-Home Message

The equine back is a well-designed structure in the properly conformed horse. However, when poor conformation is involved and/or inappropriate tack is used, serious problems can arise. ⚡

ABOUT THE AUTHOR

Les Sellnow is a free-lance writer based near Riverton, Wyo. He specializes in articles on equine research, and he operates a ranch where he raises horses and livestock. He has authored several fiction and non-fiction books, including Understanding Equine Lameness, Understanding The Young Horse, and The Journey of the Western Horse, published by Eclipse Press and available at www.ExclusivelyEquine.com or by calling 800/582-5604.

FURTHER READING

AAEP Convention 2005: "Treating Sore Backs Table Topic," www.TheHorse.com/emag.aspx?id=6537.
"Fitting the Saddle to the Withers," www.TheHorse.com/emag.aspx?id=5700.
"Hunter's Bump," www.TheHorse.com/emag.aspx?id=4649.
"Understanding Back Pain," www.TheHorse.com/emag.aspx?id=3901.

Body Builders: Muscles

BY LES SELNOW

Muscles are one of the most important components in the equine body. Without them, the horse would be unable to walk, chew food, digest it, or even swish his tail. Muscles comprise the largest tissue mass in the horse's body. There are various types of muscles performing a wide variety of duties, but basically they all function in the same general way—a period of contraction or shortening of muscle fibers, followed by a period of muscle relaxation or lengthening of muscle fibers.

A horse's conformation and muscle types can determine how well he can perform certain tasks, but all horses are subject to muscle injury and disease

In this article, we'll take a look at how equine muscles function and are nourished, as well as examine some of the problems that have surfaced, such as hyperkalemic periodic paralysis (HYPP) and tying-up. As has been the case throughout this series, we will draw on a wide variety of sources, including textbooks. However, a couple of researchers deserve specific mention. Much of the information concerning description of muscle structure comes from a paper authored by Craig H. Wood, PhD, coordinator of Distance Learning at the University of Kentucky, and published in the *Horse Industry Handbook*. When we discuss HYPP, the work of Sharon Spier, DVM, Dipl ACVIM, PhD, associate professor at the University of California, Davis, becomes a source of information. No discussion on tying-up should be conducted without drawing on the research of Stephanie Valberg, DVM, PhD, professor of large animal medicine and director of the Equine Center at the University of Minnesota.

Editor's Note

This is the eighth in a 12-part series of articles on equine anatomy and physiology. Future topics include the tendons and ligaments, the digestive system, the circulatory and respiratory systems, and the reproductive system.

DR. ROBIN PETERSON ILLUSTRATION



Types of Muscles

The three muscle classifications are smooth, cardiac, and skeletal. The first two are involuntary or automatic, which means they function as needed without having to be called into action for a specific need. Skeletal muscles are voluntary; the brain sends a signal to the muscles via nerves, and the muscles react accordingly.

Non-skeletal muscles are basically the same for all horses. Smooth muscles are located in such places as the digestive tract, respiratory and circulatory systems, as well as the urogenital system. These muscles are many and varied, and they respond to stimuli within the respective systems.

There are three major types of cardiac muscles: atrial muscle, ventricular muscle, and specialized excitatory and conductive muscle fibers. Cardiac muscle is controlled by the central nervous system.

Skeletal Muscles

The skeletal muscles are striated in design, with a single muscle being composed of numerous muscle bundles made up of muscle fibers. There are two general classifications for these muscles fibers: Type 1 and Type 2.

Generally speaking, the slow-contracting Type 1 fibers are utilized heavily by horses involved in non-strenuous activity, while the fast-contracting Type 2 fibers are more often used by equines athletes, such as a racing Thoroughbred or Quarter Horse.

Wood writes that the muscle fibers contain several hundred to several thousand myofibrils. Each myofibril, in turn, has many myosin and actin filaments. These filaments are large polymerized protein molecules that are responsible for muscle contraction.

He also tells us that skeletal muscle contains a sarcoplasmic reticulum (calcium pump) and a tubular system. The calcium pump, Wood reports, is extremely important in muscle contraction through the release and uptake of calcium ions, which are involved in the contraction process.

Muscles are signaled to contract via nerve impulses. Relaxation occurs when the nerve impulses cease.

The slow-contracting or slow-twitch

Type 1 fibers do not oxidize the muscle fuels rapidly and, as a result, are fatigue resistant. They are aerobic in nature, which means they utilize fuel in the presence of oxygen. Primarily, these fibers are used for long-term, non-strenuous work.

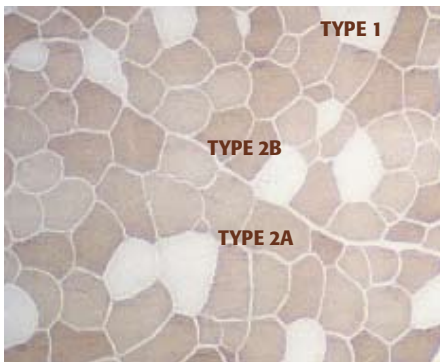
By comparison, Type 2 fibers are fast-contracting (fast-twitch) and tend to burn up muscle fuel in a hurry. As a result, they fatigue rapidly when compared to their Type 1 counterparts. Type 2 fibers are further classified as Type 2A, Type 2B, and Type 2C. Type 2A fibers are recruited for speed or an increase in strenuous activity. Type 2B fibers are called on for sustained bursts of speed or effort that carry the horse to the point where anaerobic energy—the type provided without oxygen—is required as an energy source.

Type 2B fibers contract with a maximum velocity that is 10 times that of Type 1 fibers and three times that of Type 2A fibers.

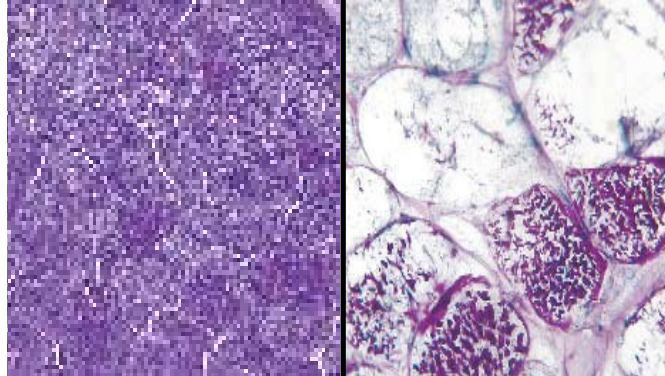
Type 2C fibers are classified as transitional and can serve as either a Type 2A or Type 2B. Research has demonstrated that racing Thoroughbreds and Quarter Horses have more Type 2 fibers than Type 1.

It is estimated that 80-90% of the muscle fibers in Thoroughbreds and Quarter Horses are of the fast-twitch or Type 2 variety. Standardbreds and Arabians have an intermediate number, about 75%. A heavy hunter or a draft horse, by comparison, would have a preponderance of Type 1, or slow-twitch, fibers.

Training can have a bearing on muscle fiber composition. For example, the number of Type 2A muscles fibers will increase in Thoroughbreds and Standardbreds as they are trained to race at longer distances.



A cross section of Type 1 (slow-contracting) and Type 2 (fast-contracting) muscle fibers.



Skeletal muscle from a normal foal (left) compared to a horse with PSSM (right). The PSSM horse has an accumulation of abnormal polysaccharide (dark purple stains).

COURTESY DR. STEPHANIE VALBERG

The amount of adenosine triphosphate (called ATP, supplier of energy to cells in the body) required by a working muscle is dependent on the effort being expended. For example, when a horse is just ambling across the pasture at a slow walk, very little energy is required, and Type 1 fibers are utilized. The fuel for these muscle fibers is a combination of glycogen (the main form of carbohydrate storage), glucose (sugar), and fat, with the emphasis on fat during non-strenuous activity. However, when the horse breaks into a trot, the scenario changes. Now, Type 2A fibers are recruited. If speed is increased to a run, Type 2B fibers might be brought into play.

When this happens, more glycogen and/or glucose is needed as fuel through a process known as glycolysis. This involves the breaking down of glucose or glycogen into energy (ATP) without oxygen and, thus, is an anaerobic reaction. Glucose is the end product of carbohydrate metabolism and is the chief source of energy for living organisms. Excess glucose is converted to glycogen and is stored in the liver and muscles for future use.

Thoroughbreds travel at a high rate of speed during a race, with Type 2 muscle fibers being recruited along the way. Because this relatively high rate of speed requires a continued burst of energy, it isn't long before the utilization of fat and glycogen stores by the muscles is unable to supply all of the energy required and anaerobic glycolysis (without the presence of oxygen) occurs with its more rapid burning of glycogen. The lactic acid that accumulates as the result of glycolysis can bring with it an early onset of fatigue.

We can compare lactic acid to exhaust from a gasoline engine. Both lactic acid and engine exhaust are by-products of fuels being burned to provide energy. The gasoline engine must emit the exhaust in order to continue functioning properly. Likewise, the horse's muscles must rid themselves of lactic acid for optimal functionality. When lactic acid accumulates faster than it can

COURTESY DR. CRAIG WOOD



Skeletal muscles are striated in design. A single muscle is composed of numerous muscle bundles made up of either Type 1 or Type 2 muscle fibers.

be dissipated, the working muscles are compromised, and the horse is fatigued.

It is different when an endurance horse competes. It normally travels at slower speeds where muscles can rely heavily on aerobic energy generation. As a result, when an endurance horse becomes fatigued, it is often the result of glycogen depletion—running out of fuel—rather than a build-up of lactic acid.

Oxygen for Fuel

It quickly becomes apparent that the most important commodity for the equine muscles to function appropriately is oxygen, even though a portion of its energy might be produced anaerobically during strenuous exercise. Oxygen is inspired into the lungs and is conveyed by the bloodstream to the working muscles.

The average, healthy horse at rest has no trouble inspiring an appropriate amount of oxygen to fuel the muscles, but things can change rapidly when the horse is performing at speed. Researchers have conducted countless experiments using treadmills to measure the amount of oxygen the exercising horse inspires.

These studies have revealed that the strenuously exercising horse might be required to inspire up to 90 liters of oxygen per minute.

To achieve this, the horse's respiratory rate might exceed 150 breaths per minute (the normal range is 8-12 breaths per minute).

Form and Movement

Conformation is involved in the way that muscles function and also is involved in determining what disciplines are right for a particular individual. We have already indicated that the thickness and massiveness of

the draft horse's muscle structure adapt it for power at the walk.

When walking, the draft horse is capable of moving heavy loads. However, its muscle structure is not designed for it to travel at a high rate of speed. Conversely, the angular form, long legs, and well-muscled rear quarters of the Thoroughbred allow it to move fluidly at speed, but it does not have the muscular strength to move heavy loads at the walk.

Within these respective groupings, however, conformational differences can have a strong bearing on how efficiently the muscles function.

For example, a racehorse with straight shoulders and pasterns will have a short stride. This means that the muscles must work harder via more frequent strides for this horse to reach a particular rate of speed. Its counterpart, with appropriate conformation, will have a fluid stride that will cover more ground and reach the same rate of speed with much less effort.

Various disciplines also bring with them certain muscle conformation requirements. The cutting horse, for example, needs a heavily muscled rear quarters because it is required to stop and pivot on its rear legs when preventing a cow from returning to the herd. The same is true of a reining horse, which is required to slide to a stop and spin. A roping horse that is used by a header in team roping, on the other hand, needs powerful muscles in the shoulders to turn a steer so that it is positioned for the heeler to throw his loop.

Injury and Disease

Injury to muscles can limit their ability to function properly. The same is true of some afflictions that have surfaced. One of them is HYPP. This is a muscular affliction

that has been traced to a genetic defect in the Quarter Horse stallion Impressive.

Earlier it was noted that muscles receive signals from nerves to react. As part of this process, a membrane "pore" or channel in the muscle opens and closes, allowing for exchange of the electrolyte sodium from outside to inside of the muscle cell. Proper functioning of the sodium channel is vital for electrical stimulation and contraction of the muscle fibers.

In horses with HYPP, this channel does not function properly, and horses so afflicted often are characterized by intermittent episodes of muscle tremors, manifested by generalized or localized shaking, trembling, and weakness. In severe cases, the horse might suffer an episode of paralysis that could cause its death through cardiac arrest or respiratory failure.

Tying-up (known as recurrent exertional rhabdomyolysis) is another affliction of the muscles. It generally is manifested in one of two forms. One form is called polysaccharide storage myopathy (PSSM) and has been noted in Quarter Horses, Paints, Appaloosas, draft horses, draft crosses, warmbloods, and a few Thoroughbreds.

With PSSM, glycogen accumulates in the muscle, but the muscle is unable to utilize it. In essence, the muscle has an abundance of fuel, but is unable to burn it to produce energy. Minus the energy that the glycogen is designed to supply, these horses develop muscle cramps and stiffness.

Treatment of horses with this affliction involves supplying them with alternative sources of energy, such as a diet high in fat rather than high in carbohydrates.

There are more types of tying-up, some of which show up in excitable young racing Thoroughbred fillies and might be genetic in origin.

Take-Home Message

More is being learned about muscles and how they function. The good news about equine muscles is that they are adaptable. Through exercise and conditioning, they can be prepared and conditioned for diverse activities in such a way that they function efficiently and stave off fatigue in order to avoid injury. 🐾

ABOUT THE AUTHOR

Les Sellnow is a free-lance writer based near Riverton, Wyo. He specializes in articles on equine research, and he operates a ranch where he raises horses and livestock. He has authored several fiction and non-fiction books, including Understanding Equine Lameness, Understanding The Young Horse, and The Journey of the Western Horse, published by Eclipse Press and available at www.ExclusivelyEquine.com or by calling 800/582-5604.

Tendons & Ligaments

BY LES SELLNOW

Tendons and ligaments in the horse are the “belts” and “cables” that hold bones in place and allow the muscles to do their jobs in creating propulsion—forward, backward, sideways, and up and down. Because of the workload often put upon them, tendons and ligaments are frequent sites of injury and disease.

What are tendons and ligaments?

Dorland's Illustrated Medical Dictionary:

Tendon—A fibrous cord by which muscle is attached to bone.

Ligament—A band of fibrous tissue that connects bones or cartilages, serving to support and strengthen joints.

Many athletic horses suffer tendon and ligament injuries, which can end a competitive life if not handled quickly and effectively

To go into detail about every tendon and ligament would fill several textbooks, which is something that's already been done. Instead, we will concentrate on the tendons and ligaments in the limbs, especially the forelimbs, which often are the sites of injury and disease. We will examine their construction, how they function, and what can happen when something goes awry.

Once again, we've utilized multiple sources, including textbooks, but one source has been most helpful: Nathaniel White II, DVM, MS, Dipl. ACVS, director of the Marion duPont Scott Equine Medical Center, part of Virginia Tech in Leesburg, Va.

Injury and Performance

The importance of maintaining healthy tendons and ligaments is borne from the fact that injuries to that part of the anatomy can quickly end a performance horse's career, and has done so in a number of instances.

One British researcher has estimated that more than 30% of horses involved in racing and other forms of competition throughout Europe suffer from some sort of tendon injury or problem as the result of



Editor's Note

This is the ninth in a 12-part series of articles on equine anatomy and physiology. Future topics include the digestive system, the circulatory and respiratory systems, and the reproductive system.

DR. ROBIN PETERSON

the vigorous exercise involved in running, jumping, and dressage.

White has stated that he doubts the percentage would be quite that high in the United States, but feels it could very well be that high in the United Kingdom because racehorses there usually compete on turf. The soft, yielding turf places substantial stress on the tendons and ligaments.

American horses, on the other hand, tend to sustain more joint and bone injuries than their European counterparts because American horses often race on harder dirt surfaces.

The wonder isn't that tendons and ligaments sustain injury, but rather that they aren't injured more often. With a Grand Prix jumper, for example, the tendons of the foreleg are asked to do the near-impossible. The tendons often are stretched to the limit and beyond when a horse lands after clearing a six-foot jump.

Cases in Point

Deep digital flexor tendons and the superficial flexor tendons play important roles in the horse's movement. As does the suspensory ligament, which originates at the upper end of the third metacarpal bone and the lower edges of the distal row of carpal bones.

Tendons and ligaments are similar in structure, but, generally speaking, tendons are more flexible and have more stretching capability. Both are made up of collagen fibers that are arranged lengthwise so that they are capable of stretching.

Collagen is the tough protein substance found in skin, tendons, bone, cartilage, ligaments, and all other connective tissues, including fascia (flat layers of fibrous tissue that separate different tissue layers). Collagen allows tendons and ligaments to stretch and contract and also gives them their toughness.

The superficial flexor tendon is most readily visible because it runs down the back of the cannon bone close to the skin. It originates at the superficial flexor muscle just behind the elbow in the front legs and just behind the stifle in the rear limbs. It travels downward, splitting after it passes over the sesamoid bones, and attaches

to the short pastern bone (P2). Along the way, the superior check ligament connects the superficial flexor tendon to the radius just above the knee.

The deep flexor tendon originates with the deep flexor muscle, also located behind the elbow. It runs between the superficial flexor tendon and the cannon bone and ultimately attaches to the coffin bone (P3). Along the way, the inferior check ligament connects the deep flexor tendon with the cannon bone just below the knee. The role of the check ligament is to limit or "check" the movement of the tendon so it isn't over stressed.

The digital extensor tendon begins with the digital extensor muscle in the same general area as the two flexor tendons, only on the forward (cranial) portion of the leg rather than the rearward (caudal) side. It continues downward along the front of the cannon bone all the way past the pastern, ultimately attaching to the coffin bone.

The flexor tendons are designed to move—or flex, as the term implies—the leg and hoof in a rearward motion, and the extensor tendons allow the limbs to be brought forward, or extended. A greater stress is placed on the flexor tendons than on the extensors.

As the horse's weight descends, the knee joint is straight or even overextended (bent backward), stretching the flexor tendons, but putting less pressure on the extensors. Most tendon injuries and disease involve the two flexor tendons, with the superficial flexor tendon being the one most apt to "bow" or suffer inflammation.

The reason the word "bow" is used is that when the fibers tear, inflammation and swelling cause the tendon to bulge or bow outward.

Another important part of the leg apparatus is the suspensory ligament. It attaches to the cannon bone just below the knee and passes downward (distally), attaching at the sesamoid bones at the rear of the fetlock joint. At the bottom of the sesamoids the ligament splits into extensor or sesamoidean ligaments that wrap around to the front of the long pastern bone (P1).

The suspensory ligament is vital for supporting the fetlock. When abnormalities or injuries occur that weaken the suspensory ligament, there often is a dropping of the

fetlock as the horse stands or moves.

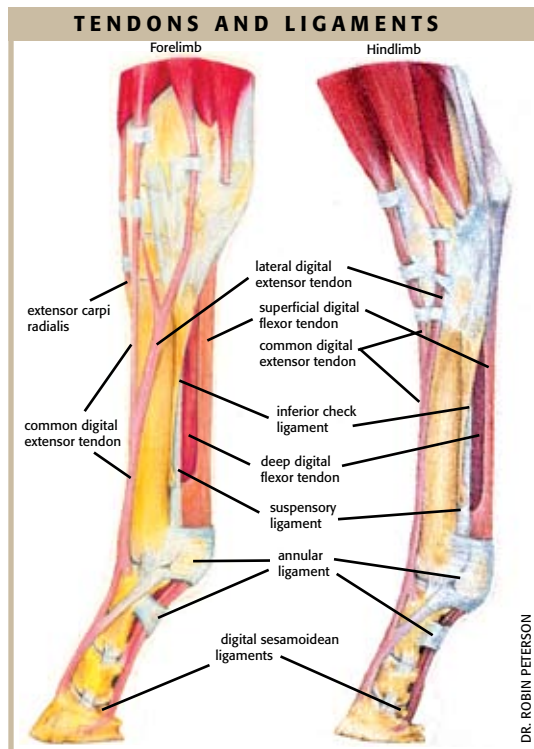
At the fetlock, another ligament—the volar annular ligament—wraps around the entire joint and attaches at the lower end of the third metacarpal bone and the upper edges of P1. One of its prime functions is to keep the tendons in place. (When the deep flexor tendon is injured, it quite often is at this point. Many practitioners say that this is the most difficult tendon injury to deal with because it's encased in a strong tendon sheath.)

While the digital muscles provide the power to raise, lower, and bend the legs at the knee, ankle, or hock, the tendons are the real workhorses. Each time a horse takes a step, the tendons and ligaments come into play. In addition to providing flexion, they serve as part of the stay apparatus that allows a horse to stand and even sleep on its feet.

Tendon Injury

Each tendon is enclosed in a sheath. Thinner areas of the sheath, such as the area behind the cannon bone, are often sites of injuries. A thick sheath encases the tendons at the point where they pass behind the fetlock. It would appear that nature has provided additional protection for the tendon at this point because this is where there is the most friction and pressure, especially when the horse is traveling at speed. The sheath is lubricated with synovial fluid to eliminate friction as the tendon moves.

While we think of the tendons as cables



DR. ROBIN PETERSON

that allow the muscles to function, they also serve as shock absorbers. Tendons can help dissipate concussion that otherwise would be borne by joints, bones, and muscles.

What we really have here is a rather elaborate cable and pulley system that allows the legs to move forward and rearward and, at the same time, supports the weight of the horse and absorbs concussion. All of the parts—bones, ligaments, cartilage, and tendons—are designed to interact and function efficiently. When injury or disease prevents this, the results can be dramatic. As the horse compensates for injury to one aspect of the apparatus, it might have a harmful effect on the other components, and they will be compromised as well.

Basically, there is a stress/strain relationship involved when the tendons are brought into play. Stress or load is applied when the horse bears weight on each limb, which is accommodated by an equivalent lengthening (strain) of the tendon.

During exercise, a horse's tendons might stretch and retract from one to three inches. When the tendon is pushed beyond its "strain" capacity, injury is the result. The damage normally involves rupturing of the tendon's collagen fibers when they are stretched beyond their capacity. This results in inflammation, soreness, and an inability of the limb to function normally.

Most serious tendon injuries occur to the front limbs for obvious reasons. First, 60-65% of the horse's weight is carried on the front end. Second, when a horse travels at speed, there is one point in every stride where the animal's entire weight descends on a single foreleg. This translates into extraordinary strain on the flexor tendons in that leg as well as on the entire suspensory apparatus. The same is true of Grand Prix jumpers when they land and all of the concussion is absorbed by the front legs.

When injury occurs, there often is great variation as to severity. The rule of thumb is the more fibers that are torn, the more serious the injury and the longer the healing and recuperation period will be.

Diagnosing Injuries

Tendon injuries today can be examined with ultrasound. The severity of defects or lesions in the injured tendon is rated on a scale of one to four, according to how they appear on the ultrasound images. Lesions appear as an ultrasound echo termed a hyperechoic (partial loss of echoes) or an anechoic (total loss of echoes) region, usually in the center of a tendon. The greater the loss of echoes, the more severe the injury,

Following is the numerical rating:

Type 1 Tendon enlargement with lesions appearing only slightly hyperechoic (darker) than usual. They represent minimal disruption of the fiber pattern and minimal infiltration of inflammatory fluid.

Type 2 Lesions are approximately half echoic and half anechoic. They represent disruption of the fiber pattern and local inflammation.

Type 3 Lesions are mostly anechoic and represent significant fiber tearing.

Type 4 Lesions are totally anechoic. They appear as black areas within a structure and indicate almost total fiber tearing with hematoma (blood-filled) formation.

It is estimated that a tendon can stretch up to 8% before the fibers begin tearing.

Ligaments are not immune to injury and disease. When injuries occur to ligaments in horses, they often involve the suspensory ligament. Unlike tendon injuries, ligament injuries often occur in both front and rear limbs.

Treatments

Treatment of a tendon injury, according to White, is a combination of acute therapy and long-term rehabilitation. The goal is to reduce inflammation, maintain blood flow, and decrease the formation of scar tissue.

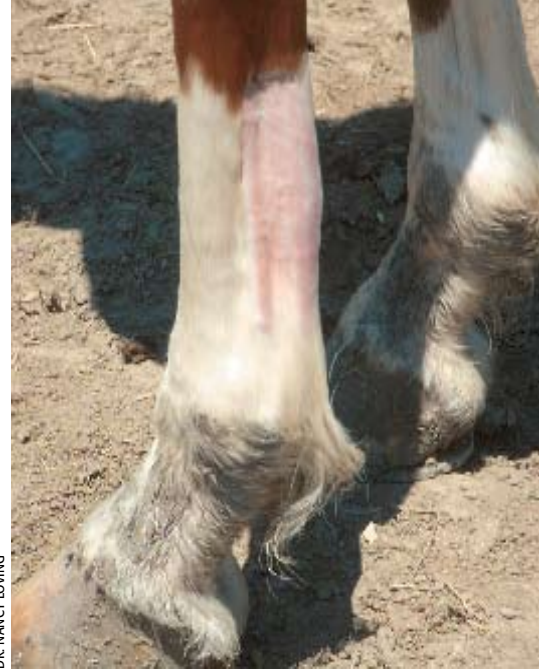The initial therapy includes systemic and local anti-inflammatory therapy. Phenylbutazone therapy for five to seven days is indicated, and the anti-inflammatory DMSO is applied topically for seven to 10 days. Ice or cold water is applied for the first seven to 10 days, depending on the amount of swelling.

The injection of hyaluronate acid around the tendon or administered intravenously can also have beneficial anti-inflammatory effects, according to White.

Another important aspect of acute treatment, says White, involves providing support for the injured tendon in the form of wraps or bandages. But, they must be properly applied. Adequate padding is a must to avoid further injury from constriction of the already injured tendon.

Rest is the primary treatment, according to White. He says stall rest with hand walking is normally required for the first one to two months after the injury. Further increases in activity, White says, are determined by the ultrasonic appearance of the tendon. The core lesion should diminish within the first two months, followed by decrease in the cross-sectional area.

Turnout is often recommended, but in some cases, controlled exercise, including



DR. NANCY LOVING

When fatigue is combined with overstretching, a bowed tendon becomes a possibility.

riding under saddle and swimming, can be helpful in the remodeling phase of tendon healing. White says most racehorses can start galloping after four to five months, but the tendon should be monitored regularly with ultrasound, using increased scrutiny when sprint work is initiated. Normally, he says, horses should not race before eight months after a Type 2 or greater injury. With some horses, tendons will not be ready for race-type stress until 12 to 14 months after the injury.

Research continues in an effort to find more effective treatment approaches for tendon injuries. New treatment methods include shock wave therapy and the use of hyperbaric oxygen chambers. Both approaches have produced some positive results, but more research is needed. Interest in using stem cells of bone marrow origin (not embryonic) to stimulate tendon and ligament healing is also growing.

Take-Home Message

Tendon and ligament injuries often go hand in hand with horses involved in vigorous athletic pursuits. However, many tendon and ligament injuries can be avoided through proper conditioning and training regimens and by not pushing a horse beyond its limits in racing or other competitions. 🐾

ABOUT THE AUTHOR

Les Sellnow is a free-lance writer based near Riverton, Wyo. He specializes in articles on equine research, and he operates a ranch where he raises horses and livestock. He has authored several fiction and non-fiction books, including *Understanding Equine Lameness*, *Understanding The Young Horse*, and *The Journey of the Western Horse*, published by Eclipse Press and available at www.ExclusivelyEquine.com or by calling 800/582-5604.

FOOD

Understanding the equine digestive system can make your horse healthier and give you fewer worries about gastric upset

Factory

BY LES SELNOW

The equine digestive system is a complicated factory that is designed to process small amounts of food frequently and convert them into nutrients that can be absorbed and produce energy. The same, concerning the end result, could be said of the cow, pig, dog, cat, or even man. But, the horse's digestive system is unique, and perhaps more prone to problems than most others.

This is not because of poor design, but is the result of humans changing what nature intended for the horse.

In the wild, horses have little to do but eat, stay out of the way of predators, and procreate. This means they range across the countryside, selecting immature forages that are easy to digest. They graze as they roam, consuming small amounts of food throughout the day and even at night. Under this scenario, there are few digestive problems.

However, man has altered Nature's scheme. First, he often adds workloads that require more than just grass to provide the necessary nutrition. Second, in many cases, all choices have been taken from the horse. He no longer roams at will, picking out choice spots for grazing. Instead, he is confined to pastures or paddocks where there might be little to choose from in the way of food. He eats what is there or is provided by his caretakers.

Because his owners or caretakers often have busy schedules, the horse no longer is able to eat small amounts frequently. Instead, he usually is fed a large quantity of food, and that sometimes occurs only once each day.



DR. ROBIN PETERSON ILLUSTRATIONS

Editor's Note

This is the tenth article in a 12-part series on equine anatomy and physiology. Future topics include the circulatory and respiratory systems and the reproductive system.



What all this adds up to is an assault on the horse's digestive system that it typically can't handle, and problems such as colic and founder can be the result.

The good news is researchers have been at work to return horse feeding to a proper balance. There is information available about nutrient needs for various levels of activity and conditions. For example, the working horse has different requirements than one turned out to pasture, and the lactating mare has different needs than the gelding being used for trail riding.

There also is a strong and growing emphasis on frequent feeding of small amounts of feed instead of large single portions.

In this article on the digestive system, we'll take a look at just how this "factory" is designed and how it functions. Knowledge of the factory is step number one in deciding how nutrient needs can be met for individual animals.

The Mouth

A discussion of the digestive system must begin with the mouth, because it is here that digestion gets under way.

There are three salivary glands in the horse's mouth, which can produce up to 10 gallons of saliva per day. A prime purpose of saliva is to mix with the feed being consumed so it can be formed into what amounts to moist, loosely formed balls that are easily swallowed.

There are two ingredients in saliva that help to launch the digestive process. One ingredient is bicarbonate, which buffers and protects against amino acids in the stomach. Saliva also contains small amounts of the enzyme amylase. This ingredient assists with carbohydrate digestion.

When on pasture, the eating process begins when the horse grasps grass by using a combination of the lips, tongue, and teeth. It was estimated by one researcher that the average horse will take about 60,000 "jaw sweeps" (chewings) per

day when grazing. This amount, of course, will be dramatically decreased when the horse is confined and fed hay and grain.

Incidentally, the way in which a horse is fed can have a profound bearing on the condition of the teeth that are used for grinding. Because there is not as full a jaw sweep when consuming hay and grain as when grazing, the confined horse often develops sharp edges that can hinder proper chewing.

Esophagus

The esophagus is a simple muscular tube that is between 50 and 60 inches in length, and it conveys food from the mouth to the stomach. When the horse is consuming grass and even hay, few problems involving the esophagus occur. However, when fed crunch items, such as carrots or apples, there can be problems with pieces becoming lodged if the horse does not masticate (grind or crush) the food properly.

The same can happen when consuming grain if the horse "bolts" food (consumes its food in a hurry) without chewing it properly. Because the horse has very little reflux capability, choking on food can have serious consequences.

Stomach

The stomach of the horse is very small in relation to the overall size of the animal, and it makes up only about 10% of the capacity of the entire digestive system. The stomach can vary in size from eight to 16 quarts. However, it appears to function best when only about three-quarters full—

another strong argument for frequent meals containing small quantities of feed.

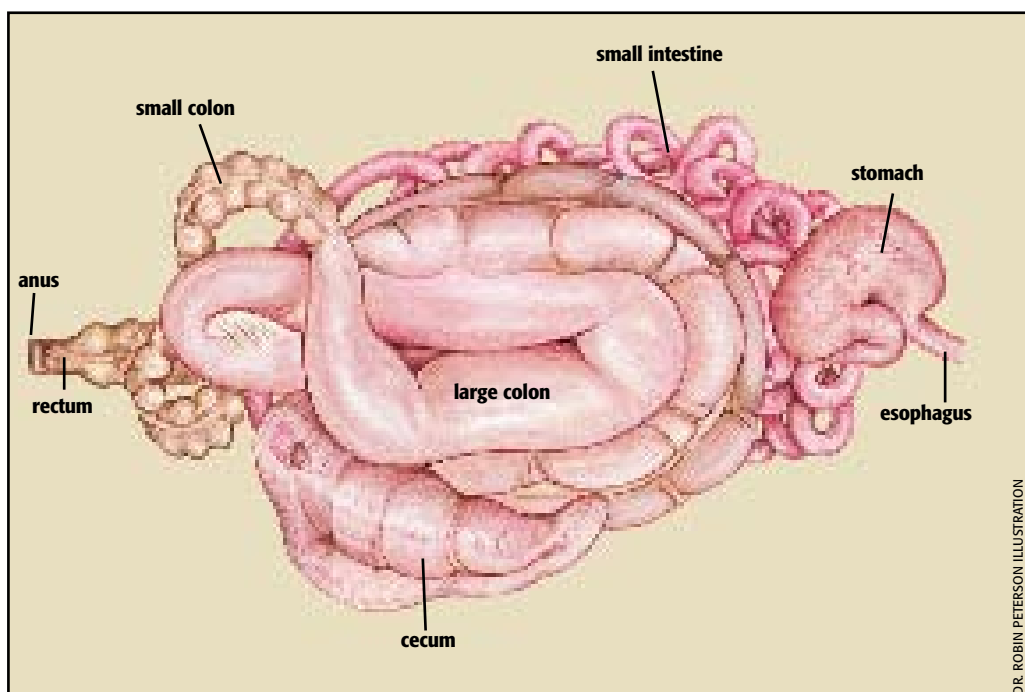
Food passes through the stomach quite quickly. In fact, by the time a horse has finished with a meal, under some circumstances, the first part of the meal consumed might already be leaving the stomach. That time often is as little as 15 minutes. While in the stomach, the food is mixed with pepsin (an enzyme utilized in the digestion of protein) and hydrochloric acid (which helps to break down solid particles).

The stomach has three main regions—saccus caecus, fundic, and pyloric. The saccus caecus region is located near the spot where the esophagus enters the stomach. It is here where hydrochloric acid first mixes with food and slows the fermentation process that began with the release of soluble sugars from the food in the horse's mouth.

It is important that there is very little fermentation in the stomach as it will cause the formation of gas, and the horse has little capability to belch or otherwise dissipate accumulating gas.

The second area is the fundic region. There the level of fermentation decreases even more. The third and final area is the pyloric region, where the stomach joins the small intestine. At this point the fermentation has almost ceased, but protein digestion increases.

Still another argument in favor of frequent feeding of small amounts of food is that the stomach does not do well when empty. There are strong acids at work in the stomach, but when there is an even flow of food, the stomach acid is put to positive



DR. ROBIN PETERSON ILLUSTRATION

use in the digestion of fats and amino acids. However, when the stomach is empty, the acid attacks the unprotected squamous cells in the saccus caecus region of the stomach (the non-glandular area of the stomach).

These attacks frequently result in the horse developing ulcers that can affect the animal's performance, appetite, and/or behavior.

Small Intestine

The partially digested food from the stomach passes into the small intestine that represents approximately 28% of the horse's digestive system. Basically, the small intestine is the tube that connects the stomach with the large intestine. On average, it is about 70 feet long and three to four inches in diameter when distended. It has a capacity of about 12 gallons.

Although there are few similarities between the digestive systems of cows and horses, the small intestine of each has about the same capacity. However, the cow's small intestine is nearly twice as long, but only about half as wide in diameter.

It is in the small intestine of the horse that serious digestive processes take place. The intestine itself secretes enzymes to facilitate the process, but the prime supplier is the pancreas, which provides enzymes that break down proteins, fats, starches, and sugars.

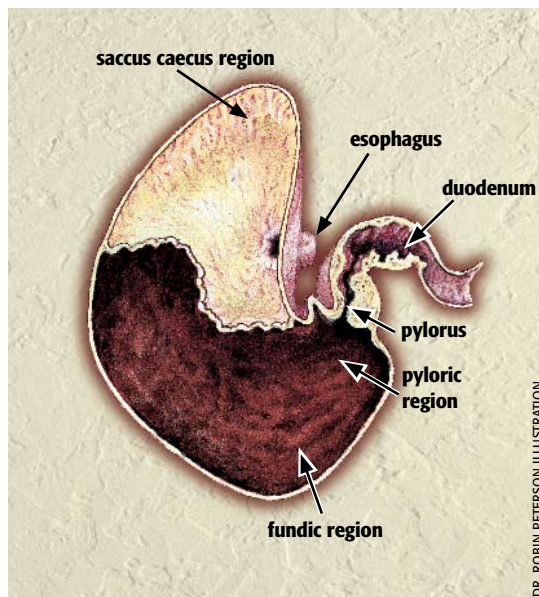
Pancreatic enzymes help digest the food while carbohydrates digest sugars and starches, and proteases break proteins down into amino acids. At the same time, lipases and bile from the liver are added to emulsify fats (make globules and suspend them as particles) in water.

The horse does not have a gall bladder (which stores bile), so bile from the liver flows directly into the small intestine.

Once the digestive process in the small intestine reaches a state of completion, the food is absorbed through the walls of the small intestine and is carried off by the bloodstream. Between 30-60% of carbohydrate digestion and absorption, and almost all amino acid absorption, occur in the small intestine. In addition, vitamins A, D, E, and K are absorbed in the small intestine, as are some minerals, such as calcium and some phosphorus.

It generally takes food 30 to 90 minutes to pass through the small intestine. The faster the food moves through the small intestine, the less time there is for the enzymes to perform their digestive tasks.

Horses are susceptible to a variety of ailments, including colic, if they ingest toxic materials. The reason is basic. With cows, the action within the rumen can detoxify feed before it reaches the small intestine. With the horse, this is not an option and the toxic material lands in the small intestine in an unaltered state and is absorbed into the bloodstream before it can be detoxified.



Large Intestine

There are five basic parts to the large intestine. They are the cecum, which is about four feet long and one foot in diameter; the large colon, which is about 12 feet long and 10 inches in diameter; the small colon, which is about 10 feet long and four inches in diameter; the rectum; and the anus.

The cecum can hold eight to 10 gallons of food and water. It is in the cecum that undigested food from the small intestine, such as hay and grass, is broken down.

The cecum is an odd-shaped organ with both the entrance and the exit being at the top. Food enters at the top, is processed, and then leaves the cecum by the same route. If a horse consumes a heavy diet of dry food matter without adequate water, impaction can occur in the lower end of the cecum, which can cause colic.

The cecum and other components of the large intestine contain active populations of bacteria and microbes that break down food through a fermentation process. Food will remain in the cecum for up to seven hours, allowing the bacteria and the microbes to handle their phase of the digestive process. Vitamins and fatty acids that result from the fermentation process are absorbed in the cecum.

The microbial populations within the cecum become specific for digestion of the type of food that the horse normally ingests. It's very important to change a horse's diet gradually in order to give the microbes an opportunity to adjust, which could take several weeks.

Microbial digestion continues in the large colon. A large share of the nutrients that result from microbial digestion absorbed here are B-group vitamins, along with some minerals and phosphorus.

It is in the large colon that a "twisted gut" usually occurs. The large colon consists of right and left ventral colons and the dorsal colon. The ventral colons have a sacculated construction, which means there are a series of pouches involved. The structure is designed to efficiently digest large quantities of fibrous materials, but the pouches or sacs can become twisted and can fill with gas during the fermentation process. The result, in either case, can be a serious case of colic.

By the time food reaches the small colon, nearly all of the nutrients have been digested. Basically, what remains is matter that is not digestible by the horse. The prime function of the small colon is to reclaim excess moisture and return it to the body. In the process, fecal balls are formed, which can be passed through the rectum and are expelled out the anus.

The whole process of ingesting food, digesting it, and expelling waste material can take from 36 to 72 hours on average.

Take-Home Message

The horse's digestive system is a complex grouping of organs that is designed for the free-grazing animal. Because of man's constraints on the movement and feed choices of domestic horses, problems can arise.

Horse owners who understand how the digestive system works can better manage their horse's feeding in order to get the best nutrition, with the least number of complications. 🐾

ABOUT THE AUTHOR

Les Sellnow is a free-lance writer based near Riverton, Wyo. He specializes in articles on equine research, and he operates a ranch where he raises horses and livestock. He has authored several fiction and non-fiction books, including *Understanding Equine Lameness*, *Understanding The Young Horse*, and *The Journey of the Western Horse*, published by Eclipse Press and available at www.ExclusivelyEquine.com or by calling 800/582-5604.

BY LES SELLNOW

There are few similarities between horses and automobiles, but in a manner of speaking, the horse's circulatory and respiratory systems constitute its engine. The food a horse consumes is its fuel. The fuel is converted into nutritional energy that powers the muscles. The respiratory system provides oxygen to facilitate metabolism, and the cardiovascular or circulatory system delivers the oxygen and nutrients to tissues as well as carrying off waste products that are produced when the "engine" is running.

We'll take a close look at these two systems and the manner in which they function.

Respiratory System

The purpose of the respiratory system can be stated simply and succinctly: It functions to exchange oxygen and carbon dioxide. Oxygen is inspired for use by the tissues, and carbon dioxide (CO₂) is exhaled as a waste product.

The amount of oxygen required and the volume of CO₂ produced varies with the level of exercise. During intense exercise, the tissues require a great deal more oxygen than when the horse is at rest, and, strenuous exercise, of course, means more CO₂ must be removed. To accomplish all that is required during exercise involves an increased respiration rate.

Before we get involved with that, let's take a look at how air is inspired and processed by the equine respiratory system.

It all starts with the nostrils. There has long been casual debate on whether the size of a horse's nostrils influences the amount of air inspired. Some would argue that nostrils that can flare widely are capable of inspiring a greater quantity of air, while others will say that there is no scientific evidence to prove that point. Whatever the case, the air passes through the nostrils and along a rather lengthy nasal cavity. The fact that the horse's nasal cavity is longer than most species provides an assist during cold weather because the cavity helps warm the air before it reaches the lungs.

The air then passes over the larynx and pharynx. When everything is working as it should, there is a smooth flow of air or food through this general area. When the horse swallows food, the pharynx and soft palate are positioned so food is moved into the esophagus rather than the trachea. When the horse is breathing, but not swallowing, there is an open channel into the

Of BLOOD & BREATH

The circulatory and respiratory systems work together to fuel the horse's body



DR. ROBIN PETERSON ILLUSTRATION

Editor's Note

This is the eleventh article in a 12-part series on equine anatomy and physiology. Next month's topic is the reproductive system (stallions and mares).

trachea. The larynx also functions as barrier to prevent food from entering the trachea.

After passing through the trachea, the inspired air arrives at the bronchial trees within the lungs. The conducting airways



of the bronchial tree divide into smaller and smaller bronchi. When cartilaginous plates are no longer present in the walls of the smallest bronchi, the airway is termed a bronchiole. The bronchioles, in turn, join with the alveolar ducts that terminate in the functional units of the lungs where gas exchange actually occurs—the alveoli.

The alveoli are small out-pouchings along the walls of the alveolar sacs and alveolar ducts. It is through the walls of these tiny pouches that gas exchange takes place. The exchange occurs between air within alveoli and blood within the capillaries in the alveolar walls.

The alveoli have very thin walls between oxygen-laden air in the lungs and the blood vessels that contain red blood cells that will carry oxygen to tissues throughout the body. It is at this point that the two systems—respiratory and circulatory—join forces. The oxygen binds to hemoglobin for transport by the circulatory system to the tissues.

The oxygen-laden red blood cells carry their valuable product to the tissues, where cell metabolism occurs and CO₂ is produced. The blood then heads back to the lungs via the veins, but this time it is loaded with more CO₂ than oxygen.

How much oxygen is taken in and how much CO₂ is expired depends on the amount of exercise. When the horse is at rest, its respiration rate is very low, with the animal sometimes taking 10 to 14 breaths or fewer per minute.

However, when strenuous exercise is involved, the respiration rate increases dramatically as the lungs move into high gear to satisfy the burgeoning demand for oxygen throughout the body. There also is a pronounced change in the effort involved. When the horse breathes while at rest, very little effort is required. However, when it breathes rapidly to satisfy the increasing demand for oxygen, it is another matter. Now, the intercostal (situated

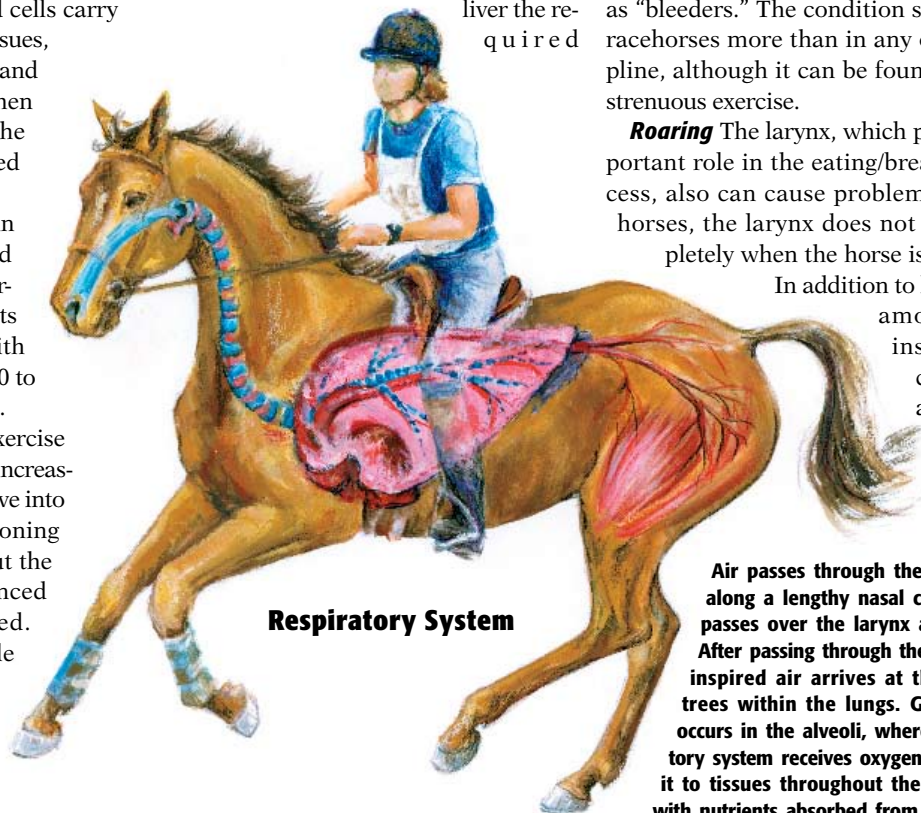
between the ribs) muscles and diaphragm are called on to expand the chest, which, in turn, allows for expansion of the lungs. The lung expansion allows for a greater quantity of air to be inspired.

The amount of air inspired and expired with each breath is called tidal volume. As indicated, the number of breaths taken per minute is referred to as respiration rate or respiration frequency. Still another term involved is minute volume. Simply put, this is the amount of air inspired and expired in one minute.

The change in minute volume during exercise can be dramatic. During rest, for example, the minute volume for a normal horse might be 150 liters per minute. During a fast gallop, this can quickly increase to 1,500 liters per minute. Because minute volume is a combination of respiration rate and tidal volume, a horse can increase it either by breathing faster, breathing more deeply, or both.

However, there is a limit to the minute volume that can be achieved during maximal exercise. When the horse is at a maximum exercise level—a heart rate that has reached 200 beats per minute and beyond—the blood leaving the lungs might not be carrying enough oxygen to adequately service the tissues. This condition is referred to as arterial hypoxia. Generally speaking, the respiratory system can deliver the re-

quired



Respiratory System

DR. ROBIN PETERSON ILLUSTRATION

oxygen—at least for a limited time—when the heart rate is 180 beats per minute or less. When the heart rate is beyond that point, it is only a matter of time before the system will begin to falter.

Limiting Problems

Unfortunately, there are circumstances other than exercise that affect the amount of oxygen that can be utilized.

RAO One of the most troublesome conditions that affect respiration is recurrent airway obstruction, or heaves, formerly known as chronic obstructive pulmonary disease (COPD). Basically, RAO is inflammation of the small bronchioles in the lungs. When RAO strikes, the lower airway system is unable to function effectively. The inflammation serves to develop obstructions within the delicate airways and air is unable to flow freely. As the condition worsens, more and more physical effort is involved when the horse inspires air.

Recurrent airway obstruction can be caused by a number of conditions, with dusty hay and a dusty environment often being implicated.

EIPH Still another condition is known as exercise-induced pulmonary hemorrhage (EIPH). Simply put, this condition involves the presence of blood in the respiratory tract during exercise. Horses with this condition often are referred to as “bleeders.” The condition shows up in racehorses more than in any other discipline, although it can be found after any strenuous exercise.

Roaring The larynx, which plays an important role in the eating/breathing process, also can cause problems. In some horses, the larynx does not open completely when the horse is breathing.

In addition to limiting the amount of air inspired, this condition also can result in noisy air

Air passes through the nostrils and along a lengthy nasal cavity, then it passes over the larynx and pharynx. After passing through the trachea, the inspired air arrives at the bronchial trees within the lungs. Gas exchange occurs in the alveoli, where the circulatory system receives oxygen and delivers it to tissues throughout the body, along with nutrients absorbed from the digestive system.

intake, often referred to as “roaring.” The technical term is laryngeal hemiplegia (or left laryngeal hemiplegia since it occurs most often on the horse’s left side, the exact cause for this is unknown).

There are many other problems that can affect the intake and exchange of air in the horse’s respiratory system. The bottom line is that healthy lungs and airways are important, especially to the exercising horse.

Cardiovascular System

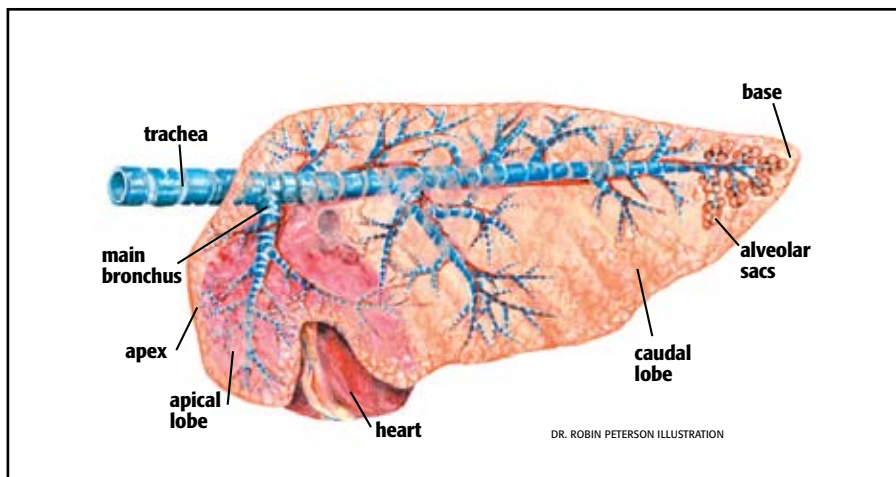
We turn now to the cardiovascular or circulatory system of the horse. This consists of blood, blood vessels through which the blood flows, and the heart that provides power for the flow of blood.

The normal adult horse weighing 1,000 pounds will have about 13.2 gallons of blood in its body. The blood is composed of red blood cells (erythrocytes), white blood cells (leukocytes), platelets, and liquid (plasma).

As indicated in the discussion on the respiratory system, the red blood cells have an iron-containing protein known as hemoglobin, which binds oxygen for transportation to the tissues. This is the primary function of the red blood cells. The main role for the white blood cells is to work with the rest of the immune system to defend against bacterial invasions. Platelets function in the blood clotting process.

The key element in the entire vascular system, of course, is the heart, whose job it is to pump blood through the circulatory system. The flow of blood is through a system of blood vessels. When blood is pumped from the heart, it travels through a network of arteries, arterioles, capillaries, and venules. After completing that part of the route in the equine body, it is returned to the heart through large veins.

The heart itself is divided into two halves. Each of the halves of this large, muscular organ (3.3-8.8 pounds) has two chambers—the atrium and ventricle. It works like this: The right atrium and ventricle pump blood into the lungs, where it is loaded with oxygen. The oxygen-laden blood returns to the left side of the heart, where the left atrium and ventricle then pump it



throughout the body.

Thus, it becomes obvious that the prime function of the circulatory system is to deliver oxygen to tissues throughout the body, along with nutrients absorbed from the digestive system. It also acts as something of a garbage disposal by delivering the end products of cellular metabolism to the lungs and kidneys for removal.

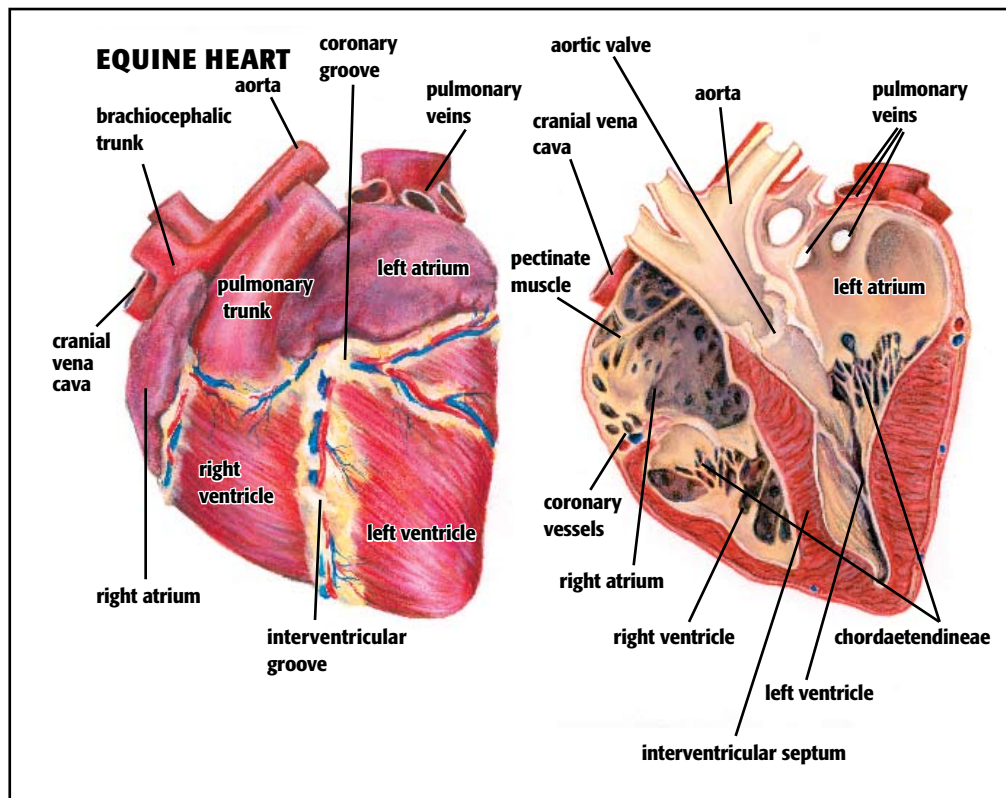
The circulatory system also fills another, less spectacular role by helping to dissipate heat by diverting blood toward the skin surface during exercise.

Earlier, we pointed out that when exercise levels increase, so does the horse’s respiration rate. The same is true for the circulatory system. As demands on the body are

increased, the horse’s heart rate goes up so that more oxygen and nutrients can be delivered to the tissues. The heart rate, quite simply, is the number of times a horse’s heart beats during a minute.

When a horse is at rest, his heart rate might be as low as 25 beats per minute. When he is exercising at the maximal rate, the heart rate can shoot as high as 250 beats per minute. Obviously, the horse can sustain this type of effort for only a short period of time. When the heart is beating at about 250 beats per minute, the cardiac output is at the rate of approximately 55 gallons of blood being pumped by the heart per minute.

Another term utilized in discussions of





the cardiovascular system is stroke volume. This is the amount of blood pumped with each beat of the heart. When we multiply heart rate by stroke volume, we come up with another term—cardiac output. This is the total amount of blood pumped by the

heart in a given time frame.

The metabolic activity of the horse determines blood flow. The higher the activity level, the higher the blood flow. The reason the heart rate increases with movement is that when a horse makes the transition from rest to exercise, heavy demands are made on limb muscles as they increase locomotion. This increased metabolic activity calls for increased blood flow, and the heart rate and stroke volume go up.

A unique aspect of the equine circulatory system is that red blood cells are stored in the spleen and are released on demand. This means during strenuous exercise, the

horse can call on reserve red cell supplies to help meet demand. It also explains why horses suffer less from altitude changes than humans. When a human goes from low to high altitude, a period of adjustment is required. The horse simply releases more red blood cells from the spleen to satisfy the increased demand for oxygen.

As mentioned earlier, blood is also utilized in the cooling process during exercise. However, if the horse is exercising maximally for a long period of time, this can result in a domino-effect series of events.

As more and more of the blood is sent to the skin during the cooling process, dehydration becomes a factor as plasma is lost in the process. Thus, it becomes something of a catch-22. The blood helps cool the horse, but the loss of plasma through dehydration means that it is losing some of the oxygen-carrying capacity to fuel tissues.

Required Reading for Responsible Horse Owners.



For over 10 years *The Horse: Your Guide to Equine Health Care* has been essential reading by responsible horse owners.

Subscribe today, and along with your full access to TheHorse.com, you'll receive 12 issues of *The Horse* filled with essential information you need to know to keep your horses healthy and strong. Order now and **SAVE OVER 72%** off the cover price. Plus, you'll get the next edition of *The Horse Source* FREE.



NO RISK. NO OBLIGATION.

Your satisfaction is absolutely guaranteed. If you're not completely satisfied, we'll send you a refund for all unmailed issues!



SUBSCRIBE NOW!

CLICK HERE or
call 1-800-582-5604

the **HORSE**
YOUR GUIDE TO EQUINE HEALTH CARE

CQ06Z236TH

When he is exercising at the maximal rate, the heart rate can shoot as high as 250 beats per minute.

As is the case with the respiratory system, a strong healthy circulatory system is needed if a horse is to remain healthy and productive during serious exercise.

Take-Home Message

While all the horse's body systems work together to keep the animal alive and active, the circulatory and respiratory systems have a special relationship. The flow of blood and oxygen can make the difference between a champion and an ordinary horse, or when problems develop, it can mean the difference between life and death. ⚡

ABOUT THE AUTHOR

Les Sellnow is a free-lance writer based near Riverton, Wyo. He specializes in articles on equine research, and he operates a ranch where he raises horses and livestock. He has authored several fiction and non-fiction books, including Understanding Equine Lameness, Understanding The Young Horse, and The Journey of the Western Horse, published by Eclipse Press and available at www.ExclusivelyEquine.com or by calling 800/582-5604.

BASICS OF LIFE

BY LES SELNOW

Reproduction in all species borders on the miraculous. How else can one describe a process where two infinitesimal entities, one from the male, the other from the female, join forces to produce living, breathing offspring?

Reproductive capability or success varies by species. Mice and rabbits, for example, are prolific producers of offspring. Horses, on the other hand, fall into a category where it is much more chancy.

When horses ran wild, this wasn't a serious problem. There were so many of them that their numbers continued to expand even though birth rate often was dictated by the availability of food and water. Once the horse was domesticated, however, organized reproduction became the order of the day. Stables that depend on selling the offspring of stallions and mares have an economic stake in breeding success. Yet, the process continues to be less than perfect, with success rates hovering in the 65-70% range, and sometimes lower.

In this article on reproductive anatomy, we'll take a look at the reproductive organs of both the mare and the stallion and discuss just how they function in their effort to produce another "miracle." Once again, sources are too numerous to mention, other than to say that much of the basic information on reproduction available today stems from research at such institutions as Colorado State University, Texas A&M University, and the University of Minnesota. There are many

others involved in reproductive research, but much of the information utilized in this article emanated from those three institutions.

The Mare


We'll begin with the mare because her role in the reproductive process is more complicated than that of the stallion. Basically, the mare serves four functions:

- 1) She produces eggs or ova;
- 2) She provides housing and nourishment for the developing embryo, which becomes a fetus;
- 3) When the fetus reaches a certain state of maturity, the mare expels it at the time of birth or parturition; and
- 4) The mare produces milk for nourishment of the young.

The mare's reproductive tract lies in a horizontal position within the abdominal and pelvic cavities. The key elements are the vulva, vagina, cervix, ovaries, oviducts, and uterus.

Vulva The vulva is the external opening of the reproductive tract. The labia are the lips of the vulva on each side of a five- to six-inch vertical slit located below the anus.

Vagina The vagina is comprised of a six- to eight-inch long muscular tube lined with mucous membranes. It connects the vulva to the cervix. The tissues of the vagina are very elastic so that it can accommodate the stallion's penis during breeding and passage of the foal during the birthing process.



*A handy guide to
the male and female
reproductive tracts*

Editor's Note

This is the final article in a 12-part series on equine anatomy and physiology. If you missed any part of the series, be sure to look for the PDF version on TheHorse.com in the coming months.

DR. ROBIN PETERSON ILLUSTRATION

Cervix The cervix provides entrance to the uterus at the end of the vagina. The cervix is about four inches long and forms a boundary between the inside and outside world with folded tissue.

When a mare is in estrus, the cervix is flaccid and open to facilitate the passage of semen. When the mare is out of estrus, the cervix is tightly closed and serves as a barrier to prevent foreign agents from entering the uterus.

Ovary The primary sex organ of the mare is the ovary. She has two of these organs that are shaped somewhat like beans and are two to three inches in length.

The ovaries are located at the forward or upper end of the reproductive structure. Their job is to produce eggs. When a female horse is born, her ovaries contain all of the egg cells that her body will ever produce. Each egg is contained in a little bubble-like container on the ovary called a follicle.

Generally speaking, not much happens with the follicles until the filly reaches puberty. At that point, one or more of the follicles will begin to grow as the result of an increase in fluid within the follicle. Normally, if nature is left to its own design, the rest of the follicles will remain small and quiescent until it is their turn.

Oviducts When the egg reaches a particular point of maturity, the follicle ruptures and the egg is discharged. The egg is then trapped in the infundibulum, a funnel-shaped membrane that surrounds the ovary.

The infundibulum narrows and becomes a coiled tube known as the oviduct. The oviduct connects to the uterus and carries the egg to that location in the wake of fertilization.

Uterus The uterus is the largest of the female reproductive organs and is capable of expansion as the fetus grows and develops. The uterus is multi-layered, hollow, and Y-shaped. The base of the Y is the uterine body, while the two branches are known as horns. Two tough, sheet-like structures, known as broad ligaments, suspend the uterus within the body cavity. There are three distinct layers in the uterus. The outermost is continuous with the broad ligaments and is known as the serous layer.

The middle layer is comprised of muscular tissue and is called the myometrium. These muscles are responsible for pushing the foal into the birth canal during parturition. The innermost layer is the endometrium, a complex mucosal membrane that contains a rich blood supply and many glands. It is the role of the uterus to house and nourish the developing fetus.

The Role of Light

A key element in the "miracle" of birth is light. The mare's reproductive activity is seasonally polyestrous, which means that she has a reproductive season and a non-reproductive season. Both are controlled by light.

The non-reproductive season is known as anestrus and comes in the fall and winter when there is little light. The reproductive season begins in the spring when days are longer, and it lasts into the summer.

However, the seasons are not all that cut and dried. In between those two basic seasons are two other cycles, known as transitional stages. One occurs just before the mare becomes reproductively active and the other occurs just prior to anestrus. During these two periods, mares generally are erratic in their cyclic and sexual behavior.

Light jump-starts the reproductive system by stimulating the hypothalamus gland located within tissues at mid-brain to produce gonadotropin-releasing hormone (GnRH). When enough GnRH is produced, the pituitary gland at the base of the brain is stimulated. The pituitary then secretes two hormones—follicle stimulating hormone (FSH) and luteinizing hormone (LH)—that act on the ovaries. Follicle stimulating hormone moves via the bloodstream to the ovaries, where it stimulates the production of one or more follicles.

When the follicles reach 20 to 25 millimeters in diameter, they secrete estrogen,

which stimulates sexual activity within the mare. It serves to prepare the reproductive tract and cervix for the arrival of sperm and causes the mare to be receptive to the stallion's sexual advances.

Luteinizing hormone facilitates maturation and ovulation of the growing, egg-bearing follicle. Ovulation occurs when the mature egg leaves the follicle and begins its trip through the oviduct and into the uterus.

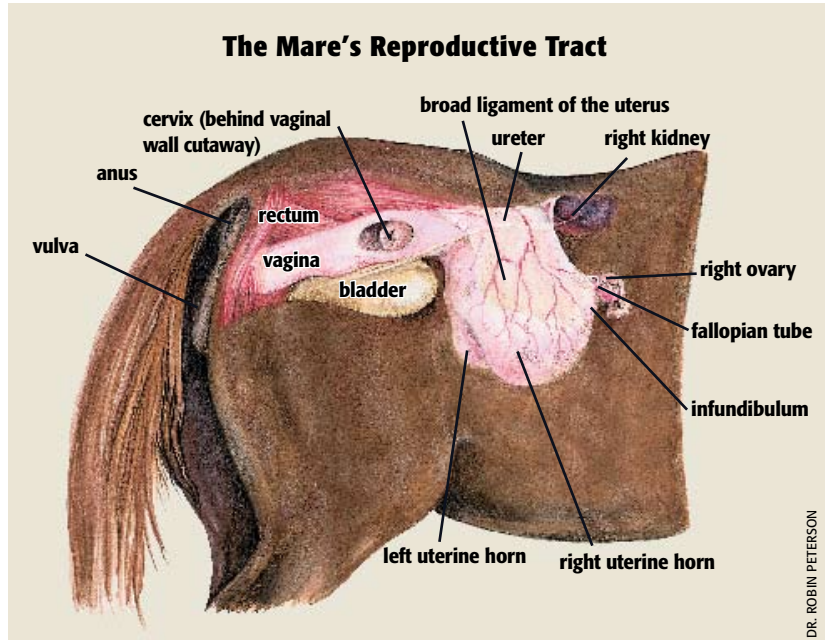
In the wake of ovulation, the estrogen level falls and the remains of the ovulated follicle are converted to form a corpus luteum (CL) or yellow body (a temporary glandular mass). Granulosa cells in the CL secrete the hormone progesterone. Its job is to shut down the secretion of the estrus-stimulating hormones and set the stage for maintenance of a pregnancy.

As progesterone carries out its tasks, the cervix closes, contractions along the reproductive tract cease, and the mare loses all interest in the stallion's advances.

What happens next is dependent on whether the mare became pregnant. If she did, progesterone will continue to function in its role of maintaining the pregnancy by suppressing other hormonal activity.

However, if the mare does not become pregnant, changes will take place to prepare the way for another try at pregnancy. The uterus will remain under the influence of progesterone for 12 to 14 days, but after that the uterus reacts.

If the mare is not pregnant at that stage, the uterine endometrium will secrete the hormone prostaglandin. The first thing prostaglandin will do is destroy CL that



DR. ROBIN PETERSON

is producing progesterone. With progesterone production shut down, the level of FSH will rise to the point where the whole cycle is started over again.

What has been described above is the way a healthy mare's reproductive system normally functions when left to its own design. However, it should be noted that some mares produce insufficient progesterone, and that a wide variety of malfunctions can occur along the way.

The Stallion

The stallion's prime function in the reproductive process is two-fold:

- 1) To produce the male reproductive cells known as sperm or spermatozoa, as well as produce the male sex hormone testosterone; and
- 2) To introduce sperm into the female reproductive tract at the proper time.

The prime sex organs of the stallion are the testes or testicles, of which there are two. Each testicle is suspended by the spermatic cord that extends from the abdomen to its attachment on the testicle.

The testicles are normally ovoid (like an egg) and will measure 80 to 140 millimeters in length and 50 to 80 millimeters in width. Each will weigh about 225 grams.

The testicles are housed in the scrotum, which is an out-pouching of the skin. It is comprised of two scrotal sacs—one for each of the testicles—and it is separated by a septum. The scrotal sacs are located on either side and in back of the penis.

The penis is the male organ of copulation and is comprised of three parts—the root, which attaches the penis to the pelvis via two strong ligaments and a pair of muscles; the body or shaft, which is the main portion of the penis; and the glans penis, which is the enlarged front end of the penis.

The major portion of the penis is formed by the corpus cavernosa (a pair of sponge-like columns of erectile tissue that becomes engorged with blood during erection). The corpus spongiosum is a small area of spongy erectile tissue that immediately surrounds the urethra. It also becomes engorged with blood during erection. The glans penis is filled with a multitude of nerve endings and becomes engorged and erect during sexual excitement.

When not erect, the stallion's penis is approximately 50 centimeters in length and 2.5 to five centimeters in diameter. The penis is contained within the sheath or prepuce, which forms two folds around the free end of the penis.

During erection, the size of the penis will

increase about 50%. However, the glans penis “flowers” or “bells” and increases in size between 300-400% during erection.

The testicles are formed within the abdominal cavity and, in the normal colt, descend into the scrotum between 30 days before birth and 10 days after birth.

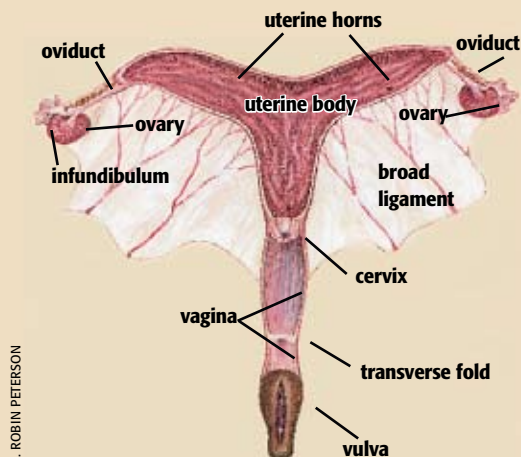
The testicle is covered with a thick layer of connective tissue called the tunica albuginea. Fused to the outer surface of this capsule is the thin visceral vaginal tunic. Supporting strands of connective tissue extend from the tunica albuginea to divide the testicles into lobules.

The non-capsular part of the testicle is called the parenchyma. It consists of seminiferous tubules (capable of producing and conveying semen) and interstitial tissue situated between the seminiferous tubules. Located within the seminiferous tubules are Sertoli cells. They are involved with the production of spermatozoa. In the adult stallion, billions of spermatozoa are produced daily in the convoluted seminiferous tubules. After leaving the seminiferous tubules, the spermatozoa travel to the epididymis, which is lightly attached to the upper surface of each testicle.

Located in the interstitial tissue between the seminiferous tubules are Leydig cells. Their prime function involves the production of testosterone.

There are three basic processes involved in the release of semen on the part of the stallion—erection, emission, and ejaculation. Erection has been discussed. Emission is the movement and deposition of sperm and fluid from the deferent duct and tail of the epididymis as well as fluids from the accessory sex glands, into the pelvic urethra. Ejaculation is the actual expulsion of the semen out through the urethra. In the stallion, ejaculation occurs as a series of strong pulsing contractions so that several successive “jets” of semen are spurted forth.

The Mare's Reproductive Tract



DR. ROBIN PETERSON

Conclusive Act

We are now at a logical conclusion. The mare's hormonal system has allowed her to be receptive to the stallion's advance. The cervix is open and relaxed. Ovulation is on schedule. The stallion does his job and sperm is ejaculated.

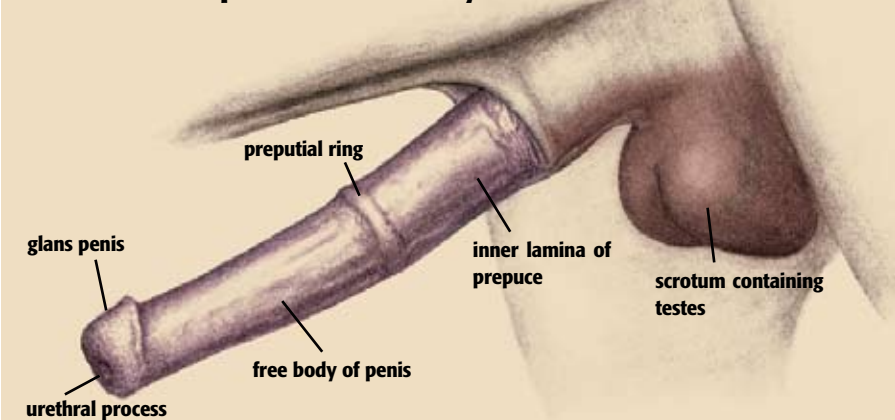
So, one might say, that for sure means a pregnancy. Not necessarily. There is a delicate time balance involved. The sperm cells live only 24 to 30 hours in the reproductive tract of the mare. The timetable is even tighter for the egg or ova. The egg remains viable for only four to six hours.

Thus, one can say, when pregnancy, followed by birth of a live foal, does occur, it is indeed a “miracle.”

ABOUT THE AUTHOR

Les Sellnow is a free-lance writer based near Riverton, Wyo. He specializes in articles on equine research, and he operates a ranch where he raises horses and livestock. He has authored several fiction and non-fiction books, including Understanding Equine Lameness, Understanding The Young Horse, and The Journey of the Western Horse, published by Eclipse Press and available at www.ExclusivelyEquine.com or by calling 800/582-5604.

The Stallion's Reproductive Anatomy



COURTESY DR. DICKSON VARNER